







Endoscopic ultrasound-guided tissue sampling: European Society of Gastrointestinal Endoscopy (ESGE) Technical and Technology Review



Authors

Antonio Facciorusso^{1†} , Marianna Arvanitakis^{1,2}, Stefano Francesco Crinò³, Carlo Fabbri⁴, Adele Fornelli⁵, John Leeds⁶ , Livia Archibugi⁷, Silvia Carrara^{8,9}, Jahnvi Dhar¹⁰, Paraskevas Gkolfakis¹¹, Beate Haugk¹², Julio Iglesias Garcia¹³, Bertrand Napoleon¹⁴ , Ioannis S. Papanikolaou¹⁵, Andrada Seicean¹⁶, Pauline M. C. Stassen¹⁷ , Peter Vilmann^{18,19}, Tony C. Tham²⁰ , Lorenzo Fuccio²¹ 

Institutions

- 1 Department of Experimental Medicine, Section of Gastroenterology, University of Salento, Lecce, Italy
- 2 Department of Gastroenterology, Digestive Oncology and Hepatopancreatology, HUB Hôpital Erasme, Brussels, Belgium
- 3 Department of Medicine, Gastroenterology and Digestive Endoscopy Unit, The Pancreas Institute, University Hospital of Verona, Verona, Italy
- 4 Gastroenterology and Digestive Endoscopy Unit, Forlì-Cesena Hospitals, AUSL Romagna, Forlì-Cesena, Italy
- 5 Pathology Unit, Ospedale Maggiore „C.A. Pizzardi“, AUSL Bologna, Bologna, Italy
- 6 Department of Gastroenterology, Newcastle Upon Tyne Hospitals NHS Foundation Trust, Newcastle upon Tyne, United Kingdom
- 7 Pancreatico-Biliary Endoscopy and Endosonography Division, Pancreas Translational and Clinical Research Center, IRCCS San Raffaele Scientific Institute, Milan, Italy
- 8 Department of Biomedical Sciences, Humanitas Pieve Emanuele University, Milan, Italy
- 9 IRCCS Humanitas Research Hospital, Milan, Italy
- 10 Department of Gastroenterology and Hepatology, Punjab Institute of Liver and Biliary Sciences, Mohali, India
- 11 Department of Gastroenterology, „Konstantopoulio-Patision“ General Hospital of Nea Ionia, Athens, Greece
- 12 Department of Cellular Pathology, Newcastle Upon Tyne Hospitals NHS Foundation Trust, Royal Victoria Infirmary, Newcastle upon Tyne, United Kingdom
- 13 Department of Gastroenterology and Hepatology, Health Research Institute of Santiago de Compostela (IDIS), University Hospital of Santiago de Compostela, Santiago, Spain
- 14 Department of Gastroenterology, Hôpital privé Jean Mermoz, Lyon, France
- 15 Hepatogastroenterology Unit, Second Department of Propaedeutic Internal Medicine, Medical School, National and Kapodastrian University of Athens, Attikon University General Hospital, Athens, Greece
- 16 Department of Gastroenterology, „Iuliu Hațieganu“ University of Medicine and Pharmacy, Cluj-Napoca, Romania
- 17 Department of Gastroenterology and Hepatology, Erasmus MC University Medical Center, Rotterdam, The Netherlands
- 18 Gastroenterology Unit, Copenhagen University Hospital Herlev and Gentofte, Herlev, Denmark
- 19 Department of Clinical Medicine, University of Copenhagen, Copenhagen, Denmark
- 20 Division of Gastroenterology, Ulster Hospital, Belfast, Northern Ireland
- 21 Department of Medical Sciences and Surgery, University of Bologna, Bologna, Italy

published online 2025

Bibliography

Endoscopy

DOI 10.1055/a-2524-2596

ISSN 0013-726X

© 2025. European Society of Gastrointestinal Endoscopy.

All rights reserved.

This article is published by Thieme.

Georg Thieme Verlag KG, Oswald-Hesse-Straße 50, 70469 Stuttgart, Germany

† These authors contributed equally.

Corresponding author

Antonio Facciorusso, MD, PhD, Department of Experimental Medicine, Section of Gastroenterology, University of Salento, Piazza Filippo Muratore 1, 73100 Lecce, Italy
antonio.facciorusso@virgilio.it

ABSTRACT

This Technical and Technology Review from the European Society of Gastrointestinal Endoscopy (ESGE) represents an update of the previous document on the technical aspects of endoscopic ultrasound (EUS)-guided sampling in gastroenterology, including the available types of needle, technical aspects of tissue sampling, new devices, and specimen

handling and processing. Among the most important new recommendations are:

ESGE recommends end-cutting fine-needle biopsy (FNB) needles over reverse-bevel FNB or fine-needle aspiration (FNA) needles for tissue sampling of solid pancreatic lesions; FNA may still have a role when rapid on-site evaluation (ROSE) is available.

ESGE recommends EUS-FNB or mucosal incision-assisted biopsy (MIAB) equally for tissue sampling of subepithelial lesions ≥ 20 mm in size. MIAB could represent the first choice for smaller lesions (< 20 mm) if proper expertise is available.

ESGE does not recommend the use of antibiotic prophylaxis before EUS-guided tissue sampling of solid masses and EUS-FNA of pancreatic cystic lesions.

ABBREVIATIONS

AE	adverse event
CH-EUS	contrast harmonic endoscopic ultrasound
ESGE	European Society of Gastrointestinal Endoscopy
EUS	endoscopic ultrasound
EUS-TA	EUS-guided tissue acquisition
FCM	fluorescence confocal laser microscopy
GI	gastrointestinal
GRADE	Grading of Recommendations Assessment, Development and Evaluation
IPMN	intraductal papillary mucinous neoplasia
LBC	liquid-based cytology
MIAB	mucosal incision-assisted biopsy
MOSE	macroscopic on-site evaluation
nCLE	needle-based confocal laser endomicroscopy
NET	neuroendocrine tumor
PCL	pancreatic cystic lesion
PICO	population, intervention, comparator, and outcome
RCT	randomized controlled trial
ROSE	rapid on-site evaluation
TTNB	through-the-needle biopsy
VOSE	visual on-site evaluation

SCOPE AND PURPOSE

This European Society of Gastrointestinal Endoscopy (ESGE) Technical and Technology Review addresses the technical aspects of endoscopic ultrasound (EUS)-guided sampling in gastroenterology, providing updated guidance on the available needles and devices, and techniques for tissue sampling.

1 Introduction

1.1 Focus and rationale

The focus of this Technical and Technology Review from the European Society of Gastrointestinal Endoscopy (ESGE) is the technical aspects of endoscopic ultrasound (EUS)-guided sampling in gastroenterology, including the available types of needle, technical aspects of tissue sampling, new devices, and specimen handling and processing.

Since the publication of the previous ESGE technical review on EUS-tissue sampling [1], several randomized controlled trials (RCTs) have been published covering many of the technical aspects and approaches to EUS-guided tissue sampling of gastrointestinal (GI) solid lesions and pancreatic cysts. Furthermore, new devices have been introduced and tested in clinical practice.

While the indications, results, and clinical impact of EUS-guided sampling are addressed in a separate Guideline from the ESGE [2,3] and in the recent ESGE core curriculum, the target audience for this technical and technology review is endoscopists who perform EUS-guided sampling.

1.2 Methodology and development process

ESGE commissioned this technical and technology review and appointed two co-leaders (A.F. and M.A.), who invited the listed authors (the panel) to participate in the development of the project. The key questions were prepared by the two leaders in cooperation with the chair of the ESGE research committee (L.F.) and then approved by the other members. The relevant clinical questions were developed according to the PICO format, which outlined the specific patient population (P), intervention (I), comparator (C), and outcome (O) for each question. The two leaders then assigned the key questions to task force subgroups.

The members of the task forces, under the supervision of the task force leaders, performed a systematic literature search to prepare evidence-based statements to address their assigned key questions. The literature search was performed on the main scientific databases up until June 2024, focusing mainly on RCTs and meta-analyses of RCTs. Retrospective or nonrandomized studies were included only if they addressed topics not covered in the RCTs. The proposed statements were discussed during an online meeting in June 2024. The Grading of Recommendations Assessment, Development and Evaluation (GRADE) system was adopted to define the quality of evidence and strength of recommendation [4].

The certainty of the evidence was defined as one of four grades: high, moderate, low, or very low (**Table 1s**, see online-only Supplementary material). The assessment of the strength of recommendation reflected the extent to which the panel was confident that the desirable effects of an intervention outweighed its undesirable effects, or vice versa, across the range of patients for whom the recommendation is intended. Recommendations fell into two categories: strong or conditional.

The final draft was also reviewed by the ESGE Governing Board, and after agreement on a final version, the manuscript was submitted to the journal *Endoscopy* for publication. All authors agreed on the final revised version.

The studies included in the current Technical and Technology review used a variety of outcomes classified in five main categories: (i) diagnostic accuracy; (ii) sample adequacy and quality; (iii) safety; (iv) technical performance of the needle/device; and (v) costs. All of these outcomes were systematically analyzed and are discussed in this document, with the recommendations listed in ► **Table 1**. Of note, EUS-guided liver biopsy was not covered in the current document as it is the subject of another ESGE Technical and Technology review.

The gold standard for diagnostic accuracy was the histologic diagnosis on the surgical specimen for resected patients and the clinical follow-up (for at least 6 months/1 year) for nonsurgical patients. Sample adequacy and the quality of the specimen were inconsistently defined across most of the included RCTs; however, a pooled analysis was performed when a homo-

geneous definition was available. Adverse events (AEs) were reported in the RCTs, although none of them was primarily designed and adequately powered to evaluate safety issues. The PICOs and search strategies are shown in **Tables 2s** and **3s**, and the table of evidence is shown in **Table 4s**.

2 Advanced EUS imaging to guide tissue acquisition

RECOMMENDATION

ESGE suggests that B-mode and contrast harmonic EUS perform equally for EUS-guided tissue acquisition in patients with solid pancreatic lesions.

Conditional recommendation, low quality of evidence.

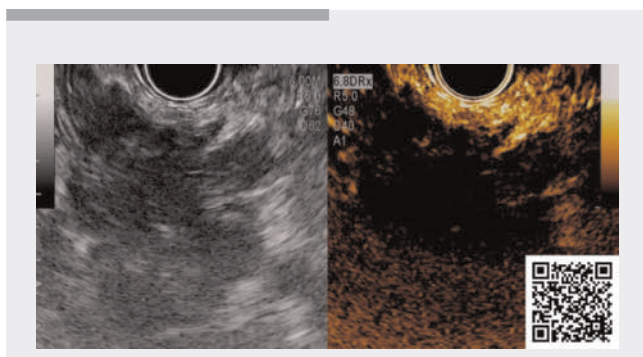
Contrast-enhanced EUS is a well-established method that combines the advantage of high resolution EUS of internal organs with the administration of ultrasound contrast agents.

Pancreatic adenocarcinoma shows a hypovascular heterogeneous pattern and less intense enhancement than the surrounding parenchyma on contrast harmonic EUS (CH-EUS), whereas neuroendocrine tumors (NETs) are typically homogeneously hyperenhancing [5]. CH-EUS may be used not only to characterize the mass, but also to suggest where to target the needle during EUS-guided tissue acquisition (EUS-TA). Indeed, CH-EUS, according to RCTs, clearly outperforms B-mode EUS in identifying the target area in solid lesions by avoiding necrotic areas, which appear avascular, and vessels [6], and in delineating the lesion [7] (► **Video 1**).

In spite of the above-mentioned advantages, CH-EUS-guided tissue acquisition (CH-EUS-TA) did not prove superior over B-mode EUS-TA in the routine setting for solid pancreatic lesions, as outlined in several RCTs, considered at low risk of bias, and meta-analyses [8,9,10,11,12,13] (**Table 5s**). The panel performed a comparative meta-analysis of diagnostic accuracy between the two approaches and did not find any significant difference (relative risk [RR] 0.99, 95%CI 0.95–1.03) (**Figs. 1s** and **2s**). The quality of evidence was downgraded owing to imprecision (95%CI crossing unity) and indirectness (owing to different contrast agents and needles being used). Therefore, a conditional recommendation with a low quality of evidence was provided that supports the equal effectiveness of the two approaches (**Table 4s**).

CH-EUS-TA could be indicated in poorly visible lesions on B-mode EUS, such as indeterminate masses in chronic pancreatitis, isoechoic lesions or suspicion of tumors in the context of acute pancreatitis. Additionally, CH-EUS allows better visualization and tissue acquisition of extravascular migratory metastases, which are identified by EUS as soft-tissue cuffs surrounding the vessel in up to 28% patients [14].

With regard to cystic pancreatic lesions, vascularized mural nodules are considered to be “high risk stigmata” for malignancy when they are ≥ 5 mm in size (sensitivity and specificity for high grade dysplasia/invasive carcinoma of 73%–100% and



► **Video 1** Contrast harmonic-endoscopic ultrasound can assist in identifying the target area for tissue acquisition in solid lesions by avoiding necrotic areas, which appear avascular, and vessels. Online content viewable at: <https://doi.org/10.1055/a-2524-2596>

► **Table 1** List of recommendations.

Recommendation	Strength of recommendation Quality of evidence
1 ESGE suggests that B-mode and contrast harmonic EUS perform equally for EUS-guided tissue acquisition in patients with solid pancreatic lesions	Conditional recommendation Low quality evidence
2 ESGE recommends end-cutting FNB needles over reverse-bevel FNB or FNA needles for tissue sampling of solid pancreatic lesions; FNA may still have a role when ROSE is available	Strong recommendation High quality of evidence
3 ESGE suggests using end-cutting FNB needles rather than reverse-bevel FNB or FNA needles for the histopathologic diagnosis of autoimmune pancreatitis	Conditional recommendation Very low quality of evidence
4 ESGE recommends EUS-FNB or mucosal incision-assisted biopsy (MIAB) equally for tissue sampling of subepithelial lesions ≥ 20 mm in size. MIAB could represent the first choice for smaller lesions (< 20 mm) if proper expertise is available	Strong recommendation Moderate quality of evidence
5 ESGE suggests end-cutting FNB needles rather than reverse-bevel FNB or FNA needles for tissue sampling of lymph nodes	Conditional recommendation Very low quality of evidence
6 ESGE recommends use of the fanning technique because it improves the diagnostic accuracy of EUS-guided tissue acquisition of solid pancreatic lesions	Strong recommendation Moderate quality of evidence
7 ESGE recommends equally the wet-suction or slow-pull techniques for EUS-FNB of pancreatic masses because they provide high rates of adequate samples and tissue integrity, and reduce specimen bloodiness compared with dry suction	Strong recommendation Moderate quality of evidence
8 ESGE recommends performing two passes with end-cutting FNB needles and three passes with reverse-bevel FNB needles. At least four passes are needed with FNA needles when ROSE is not available	Strong recommendation Moderate quality of evidence
9 ESGE suggests performing EUS-TA before ERCP in jaundiced patients with pancreatic head lesions, especially when self-expandable metal stents are being used	Conditional recommendation Low quality of evidence
10 ESGE recommends the use of ROSE when EUS-FNA is performed. ROSE is not needed for EUS-FNB, particularly with end-cutting needles, of pancreatic solid lesions and submucosal lesions	Strong recommendation Moderate quality of evidence
11 ESGE recommends the use of macroscopic on-site evaluation (MOSE) for EUS-FNB of pancreatic masses because this approach leads to high diagnostic accuracy, with the need for fewer needle passes	Strong recommendation Moderate quality of evidence
12 ESGE suggests the use of glucose level over carcinoembryonic antigen (CEA) in the cystic fluid for the diagnosis of pancreatic mucinous cysts	Conditional recommendation Low quality of evidence
13 ESGE suggests EUS-guided through-the-needle biopsy (TTNB) where the histologic diagnosis may change the clinical management of the patient. TTNB should be avoided in PCLs with communication with the pancreatic duct owing to the risk of serious adverse events	Conditional recommendation Very low quality of evidence
14 ESGE suggests the use of needle-based confocal laser endomicroscopy (nCLE) to discriminate between mucinous and non-mucinous pancreatic cysts in centers with adequate expertise	Conditional recommendation Low quality of evidence
15 ESGE does not recommend the use of antibiotic prophylaxis before EUS-guided tissue sampling of solid masses and EUS-FNA of PCLs	Strong recommendation Moderate quality of evidence

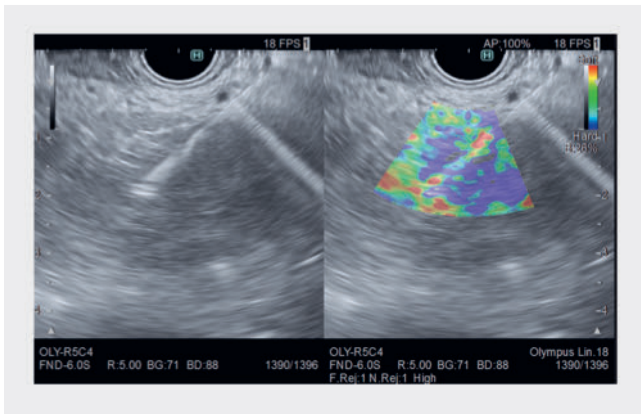
ERCP, endoscopic retrograde cholangiopancreatography; EUS, endoscopic ultrasound; EUS-TA, EUS-guided tissue acquisition; FNA, fine-needle aspiration; FNB, fine-needle biopsy; PCL, pancreatic cystic lesion; ROSE, rapid on-site evaluation.

73%–85%, respectively) and a “worrisome feature” when their size is < 5 mm [15]. CH-EUS is helpful for assessing vascularity and differentiating mural nodules from nonenhancing mucin plugs, with a reported sensitivity and specificity of 88% and 79%, respectively [16].

Elastography determines the stiffness of the lesion and pancreatic adenocarcinoma tends to show high stiffness owing to the desmoplastic reaction of the tissue. While elastography can be a useful tool for tissue characterization, there is limited

evidence on its use to target tissue sampling. Indeed, despite the promising results of a preliminary report [17], elastography-guided fine-needle aspiration (FNA) from the hardest (blue) part of the pancreatic mass (► **Fig. 1**), which is considered to have the highest suspicion of malignancy, proved not to have added utility over conventional EUS-FNA (sensitivity 90% vs. 93%) [18].

No data on the use of these ancillary techniques to target EUS-TA in extrapancreatic lesions are available.



► **Fig. 1** Endoscopic ultrasound images showing elastography-guided fine-needle biopsy of a pancreatic lesion; the needle was targeted to the “blue” area of the lesion, which represents an area with higher stiffness that is more likely to be neoplastic.

3 Needle choice for the sampling of solid lesions

3.1 Available needle types

In the last three decades, the evolution of needles has undergone a remarkable change and they are still constantly under development, with the design of innovative tips allowing for larger histologic specimens with preserved tissue architecture, and the use of tissue for genomic profiling and organoid development, which are very important in the era of oncologic personalized medicine. As a result, the current era has seen a decisive shift from FNA to fine-needle biopsy (FNB) needles, with the former’s role now mainly restricted to interventions for pancreaticobiliary access and pancreatic cysts [19].

EUS-FNA needles have limitations that are well known: their diagnostic performance is dependent on a cytopathologist to render a rapid on-site evaluation (ROSE); no histologic core tissue is possible (this is especially relevant to differentiate pancreatic cancer from autoimmune pancreatitis or chronic pancreatitis); and insufficient tissue is obtained for risk stratification to tailor anticancer therapy.

Reverse-bevel EUS-FNB needles were developed in 2011 (EchoTip ProCore; Cook Medical, Indiana, USA). They consisted of an opening at the side of the needle, with a hollow reverse-bevel architecture, which allows cutting of the tissue during backward retraction of the needle [20]. Multiple studies, including RCTs and meta-analyses, have been published comparing reverse-bevel FNB needles with standard EUS-FNA needles, with the former not having been able to establish their superiority with respect to diagnostic accuracy over the latter [21, 22]. These meta-analyses showed that both needles had similar diagnostic accuracy and sample adequacy, but ProCore FNB needles required fewer passes to establish the diagnosis (mean difference -1.2 and -0.32 , respectively) [21, 22].

Subsequently, newer “third generation” EUS needles were developed, known as “end-cutting” needles. These needle types have shown excellent diagnostic accuracy ($>90\%$), even without ROSE, and are not associated with an increased incidence of AEs [23].

Currently, four needle-tip geometries are available.

3.1.1 Franseen type

The Franseen type, which has three symmetrically distributed needle points and cutting edges (Acquire, Boston Scientific, Marlborough, USA; EchoTip AcuCore, Cook Medical, Indiana, USA; SonoTip TopGain, Medi-Globe, Germany).

The Acquire is made of cobalt–chromium and is available in 19G, 22G, and 25G sizes. The new version, the Acquire S, has a taper-point stylet to ease needle penetration. The EchoTip AcuCore EUS-FNB needle was introduced in 2024. It is made of cobalt–chromium combined with a spring-coiled sheath to enhance its flexibility; it is available only in the 22G size. The SonoTip TopGain needle is made of stainless steel, with a nitinol stylet, and has a laser engraving over the needle length for better visibility; it is available in 19G, 22G, and 25G sizes.

3.1.2 Fork-tip type

The fork-tip type has two protruding asymmetrical sharp points and six distal cutting edges (SharkCore, Medtronic, Minneapolis, USA) [24]. SharkCore needles, available in 19G, 22G, and 25G, are made of stainless steel and contain a nitinol stylet. They use a Beacon delivery system (Medtronic, Minneapolis, USA), allowing for needle removal from the sheath, maintaining the sheath in the echoendoscope.

3.1.3 Three-prong asymmetric tip

The three-prong asymmetric tip has one tip longer than the other two (Trident, Microtech, Nanjing, China). The Trident needle is made of cobalt–chromium, has laser etched markings for enhanced needle echogenicity, and it is available in 19G, 22G, and 25G sizes.

3.1.4 Menghini tip

The Menghini tip is characterized by a tapered continuous cutting edge (ProCore, Cook Medical, Indiana, USA; EZ Shot 3 Plus, Olympus, Tokyo, Japan; Sonopsy CY, Hakko Medical, Nagano, Japan). The 20G ProCore has a forward-facing bevel, antegrade core trap technology, and ReCoil stylet. The automatic recoiling pattern of the latter helps the technicians to easily manage the stylet, minimizing contamination [25]. The EZ Shot 3 Plus is made of nitinol with a side hole and a multilayer coil metal sheath, and is available in 19G, 22G, and 25G sizes. The Sonopsy CY is a 21G needle with a sharpened stylet that is directly connected to the plunger of the aspiration syringe and retracted while activating the aspiration.

3.2 EUS-FNA vs. EUS-FNB

RECOMMENDATION

ESGE recommends end-cutting FNB needles over reverse-bevel FNB or FNA needles for tissue sampling of solid pancreatic lesions; FNA may still have a role when ROSE is available.

Strong recommendation, high quality of evidence.

ESGE suggests using end-cutting FNB needles rather than reverse-bevel FNB or FNA needles for the histopathologic diagnosis of autoimmune pancreatitis.

Conditional recommendation, very low quality of evidence.

Based on previous meta-analyses that did not show a significant difference in terms of diagnostic accuracy between FNA and FNB ProCore needles [21,22], the latest ESGE Guidelines on tissue sampling recommended FNB and FNA equally in patients with pancreatic solid lesions with only a weak recom-

mendation for end-cutting FNB needles when the aim is to obtain core tissue [2].

Data across previous RCTs were incorporated in two network meta-analyses, performed by Han et al. and Gkolfakis et al. [26, 27]. Han et al. evaluated data from 29 RCTs and showed that 22G fork-tip FNB needles had the best performance in terms of pooled diagnostic accuracy, followed by the 22G Olympus needle and the 22G Franseen needle (Boston Scientific) [26]. Similarly, Gkolfakis et al. showed that Franseen and fork-tip FNB needles were the best ranked needles, especially in the 22G size [27]. Additionally, 25G Franseen or fork-tip needles did not outperform 22G reverse-bevel needles; of note, FNA needles seemed to still be competitive when ROSE was available, providing similar results to FNB in this specific setting [27].

The panel updated the literature search of the above mentioned meta-analyses, and the main characteristics of the 19 RCTs [28,29,30,31,32,33,34,35,36,37,38,39,40,41,42,43,44,45,46] that compared end-cutting FNB needles with each other or with FNA/reverse-bevel FNB needles in patients with pancreatic solid lesions are listed in the ► **Table 2**. The panel confirmed the results of the previous network meta-analysis [27], with Franseen and fork-tip FNB clearly outperforming FNA and reverse-bevel FNB (Franseen vs. reverse-bevel, RR 1.2,

► **Table 2** Randomized controlled trials comparing different end-cutting FNB needles with each other or versus FNA/FNB needles with reverse-bevel design for tissue sampling of pancreatic masses.

Author, year country	Study design	Number of patients	Age, years; sex, male, n (%)	Needle used	ROSE	Accuracy	Adequacy
Ardengh, 2020 Brazil	Cross over RCT	FNA: 20	65 9 (45)	22G	No	15/20	19/20
		FNB: 20		20G forward-facing bevel		18/20	20/20
Ashat, 2020 USA	Parallel RCT	Franseen: 39	66 56 (42) 64 56 (42)	22G	Yes	36/39	38/39
		Fork-tip: 36		22G		34/36	35/36
Asokkumar, 2019 Singapore	Cross over RCT	FNA: 20	64 16 (44)	22G	Yes	18/20	20/20
		FNB: 20		22G Franseen		18/20	19/20
Bang, 2017 USA	Cross over RCT	FNA: 46	68 28 (61)	22G	Yes	37/46	38/46
		FNB: 46		22G Franseen		43/46	45/46
Bang, 2018 USA	Cross over RCT	Franseen: 50	71 28 (56)	22G	Yes	48/50	48/50
		Fork-tip: 50		22G		46/50	46/50
Bang, 2021 USA	Parallel RCT	Fork-tip: 31	64 17 (55) 68 20 (61)	22G	No	30/31	31/31
		Menghini: 33		22G		25/33	33/33
		Franseen: 32	22G	30/32		32/32	
		Reverse bevel: 33	22G	22/33		28/33	
Chen, 2021, Canada	Parallel RCT	Fork-tip: 115	70 65 (57) 69 58 (48)	22/25G	Yes	106/115	110/115
		FNA: 120		22/25G		112/120	112/120

► **Table 2** (Continuation)

Author, year country	Study design	Number of patients	Age, years; sex, male, n (%)	Needle used	ROSE	Accuracy	Adequacy
Cho, 2020 Korea	Parallel RCT	Reverse bevel: 43	64 26 (61)	25G	No	34/43	32/43
		Forward-facing bevel: 45	64 22 (49)	20G		40/45	41/45
Crino, 2020 Italy	Parallel RCT	Fork-tip: 96	66 64 (67)	22/25G	No	91/96	94/96
		Reverse bevel: 96	64 46 (48)	22/25G		80/96	89/96
Igarashi, 2019 Japan	Cross over RCT	Menghini: 30	74 11 (37)	21G	No	27/30	27/30
		Reverse bevel: 30		22G		27/30	27/30
Kandel, 2020 USA	Cross over RCT	Fork-tip: 50	68 25 (50)	19/22G	Yes	50/50	50/50
		FNA: 50		25G		50/50	50/50
Karsenti, 2020 France	Cross over RCT	Franseen: 60	69 27 (45)	22G	No	52/60	60/60
		Forward-facing bevel: 60		20G		40/60	49/60
Mendoza Ladd, 2022 USA	Parallel RCT	Fork-tip: 22	NR NR	22G	No	NR	22/22
		Franseen: 33		22G		NR	33/33
Mizukawa, 2020 Japan	Cross over RCT	Menghini: 97	68 63 (65)	21G	Yes	86/97	93/97
		FNA: 97		22G		71/97	89/97
Mohamadnejad, 2023 Iran	Parallel RCT	Franseen: 57	60 36 (63)	22G	No	54/57	NR
		Three-prong tip: 57	61 32 (56)	22 3G		56/57	NR
Oh, 2021 Korea	Parallel RCT	25G Franseen: 70	66 39 (56)	25G	No	68/70	70/70
		22G Franseen: 70	62 40 (57)	22G		70/70	70/70
Oppong, 2021 UK	Cross over RCT	Fork-tip: 108	69 57 (53)	22/25G	No	85/108	97/108
		FNA: 108		22/25G		69/108	99/108
Tomoda, 2021 Japan	Cross over RCT	25G Franseen: 88	71 45 (51)	25G	Yes	76/88	79/88
		22G Franseen: 88		22G		79/88	82/88
Yousri, 2022 Egypt	Parallel RCT	Franseen: 50	58 28 (56)	22G	No	49/50	NR
		FNA: 50	58 29 (58)	22G		45/50	NR

FNA, fine needle aspiration; FNB, fine needle biopsy; RCT, randomized controlled trial; ROSE; Rapid On-Site Evaluation.

95%CI 1.1–1.4; Franseen vs. FNA, RR 1.2, 95%CI 1.0–1.3; fork-tip vs. reverse-bevel, RR 1.2, 95%CI 1.0–1.3; and fork-tip vs. FNA, RR 1.1, 95%CI 1.0–1.2). Therefore, end-cutting needles, such as Franseen and fork-tip FNB needles, should be preferred over FNA and reverse-bevel needles, particularly when ROSE is not available.

The quality of evidence was rated as high because the literature was based on a large number of RCTs, without evidence of

heterogeneity, indirectness, publication bias, inconsistency, or imprecision (**Table 4s**). Therefore, a strong recommendation with a high quality of evidence supported the comparison among the different needle types for pancreatic solid lesions.

The histologic diagnosis of autoimmune pancreatitis represents a great challenge for endoscopists given the need to obtain high quality core tissue for the final diagnosis [47]. The development of EUS-FNB needles has generated a great deal of

interest in the field; however, although FNB needles are supposed to improve tissue capture, previous meta-analyses found only a suboptimal diagnostic accuracy, up to 63% with FNB, although this was significantly superior to that of FNA [48]. Of note, this meta-analysis included mainly studies using reverse-bevel FNB needles as only a few reports using end-cutting needles were available at that time.

The panel updated the meta-analysis including only FNB needles and found 12 noncomparative series, with 496 patients [49, 50, 51, 52, 53, 54, 55, 56, 57, 58, 59, 60]. The characteristics of the included studies are reported in **Table 6s**.

The overall diagnostic accuracy rate of EUS-FNB in these patients was 75% (95%CI 66%–83%) (**Fig. 3s**), with superiority of end-cutting FNB over reverse-bevel FNB (80% [95%CI 70%–90%] vs. 49% [95%CI 21%–67%]; $P < 0.001$). FNB provided International Consensus Diagnostic Criteria (ICDC) level 1 histologic diagnosis in 47% of cases (38%–57%) and level 2 in 23% (16%–30%). Specifically, FNB provided a rate of definitive histopathology in those patients without a diagnosis with other criteria as high as 77% (95%CI 63%–91%). Therefore, the panel concluded that EUS-FNB with end-cutting needles should be preferred over FNA or other FNB needles in the diagnostic management of autoimmune pancreatitis. The quality of evidence was downgraded because the meta-analysis was based on non-randomized observational studies and because of inconsistency (high heterogeneity in the estimates) and indirectness (indirect comparison between different needles) (**Table 4s**). Therefore, a conditional recommendation with a very low quality of evidence was provided that supported the use of end-cutting needles in patients with autoimmune pancreatitis.

RECOMMENDATION

ESGE recommends EUS-FNB or mucosal incision-assisted biopsy (MIAB) equally for tissue sampling of subepithelial lesions ≥ 20 mm in size. MIAB could represent the first choice for smaller lesions (< 20 mm) if proper expertise is available.

Strong recommendation, moderate quality of evidence.

ESGE suggests end-cutting FNB needles rather than reverse-bevel FNB or FNA needles for tissue sampling of lymph nodes.

Conditional recommendation, very low quality of evidence.

In terms of data on EUS-TA for lymph nodes and subepithelial lesions, data are somewhat scarce. A meta-analysis of 10 studies, of which six were RCTs, comparing FNA versus FNB for subepithelial lesions showed FNB to be superior in terms of pooled sample accuracy (95% vs. 81%; $P = 0.007$), histologic core (90% vs. 65%; $P < 0.001$), diagnostic accuracy (odds ratio [OR] 4.1, 95%CI 2.5–6.8) with a lower mean number of passes (mean difference -0.75) [61].

The same group recently published a network meta-analysis comparing all the available techniques to sample subepithelial

lesions [62]. Based on eight RCTs [63, 64, 65, 66, 67, 68, 69, 70] (**Table 7s**), the authors found that EUS-FNB was significantly superior to EUS-FNA in terms of sample adequacy (RR 1.2, 95%CI 1.1–1.5), and appeared to be the best technique (surface under cumulative ranking [SUCRA] score 0.90), followed by mucosal incision-assisted biopsy (MIAB; SUCRA 0.83), whereas endoscopic bite-on-bite biopsy showed the poorest performance. Interestingly, when considering lesions < 20 mm, MIAB (a group of newer techniques involving unroofing the subepithelial lesion to expose its surface or submucosal tunneling allowing direct biopsy sampling of the lesion), but not EUS-FNB, showed significantly higher accuracy rates compared with EUS-FNA (RR 1.7, 95%CI 1.0–2.9) and ranked as the best intervention in this specific subset of lesions. As observed with solid pancreatic lesions, when ROSE was available, no difference between EUS-FNB, EUS-FNA, and MIAB was observed [62].

Therefore, as already outlined in the previous ESGE guidelines [71], the panel recommend the use of EUS-FNB or MIAB for tissue sampling of subepithelial lesions in the GI tract. MIAB could represent the first choice in the subset of smaller lesions (< 2 cm); however, owing to the risk of bleeding and complications, and the more challenging technical characteristics, MIAB should be performed in centers with high case volume and adequate expertise. The quality of evidence was downgraded because of high imprecision in the estimates owing to wide 95%CI crossing unity or failure to reach the optimal information size. Therefore, a strong recommendation with a moderate quality of evidence was provided (**Table 4s**).

As already observed with solid pancreatic lesions, a meta-analysis clearly showed that end-cutting FNB needles outperform EUS-FNA in terms of diagnostic accuracy for tissue sampling of lymph nodes (OR 1.9, 95%CI 1.2–3.0), whereas no difference was observed in the sensitivity analysis comparing reverse-bevel FNB versus FNA (OR 1.0, 95%CI 0.5–1.5) [72]. Of note, a recent large prospective Italian series of lymph nodes sampled with 22G Franseen or 25G fork-tip FNB needles showed an overall sensitivity, specificity, and accuracy of 96%, 100%, and 97%, respectively [73].

The panel updated the meta-analysis [72], including 10 studies [74, 75, 76, 77, 78, 79, 80, 81, 82, 83] that directly compared EUS-FNB versus EUS-FNA for tissue sampling of lymph nodes (**Table 8s**). Diagnostic accuracy was similar between FNB and FNA (OR 1.5, 95%CI 0.9–2.5) (**Fig. 4s**); however, FNB performed with end-cutting needles clearly outperformed FNA (pooled accuracy with end-cutting FNB needles, 89%; OR 1.9, 95%CI 1.2–3.0).

Therefore, the panel concluded that EUS-FNB with end-cutting needles could be the best option in these patients, although further data from RCTs are needed. The quality of evidence was downgraded because the meta-analysis was based mainly on nonrandomized observational studies and because of inconsistency (high heterogeneity in the estimates), risk of bias in the literature, and imprecision in the estimates (**Table 4s**). Therefore, a conditional recommendation with a very low quality of evidence was provided.

4 Sampling techniques

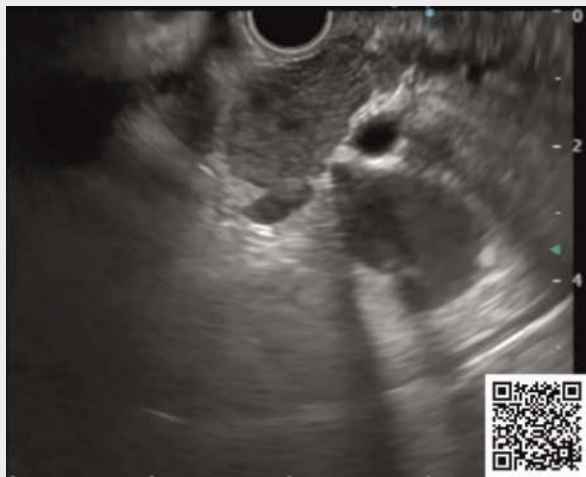
4.1 Fanning

RECOMMENDATION

ESGE recommends use of the fanning technique because it improves the diagnostic accuracy of EUS-guided tissue acquisition of solid pancreatic lesions. Strong recommendation, moderate quality of evidence.

The fanning technique allows sampling of multiple areas within the same lesion with a single needle pass by changing the needle's direction with the up/down deflection wheel (big wheel) or the elevator [84, 85] (► **Video 2**). To increase the efficacy of fanning, it is suggested that the direction of the puncture be changed after withdrawing the needle at the proximal limit of the tumor. Despite not being widely investigated, two RCTs have demonstrated that, compared with the standard technique, the fanning technique results in higher diagnostic accuracy, a lower number of passes to establish the diagnosis, and a higher percentage of patients in whom a diagnosis is achieved with just the first pass, yet with no difference in terms of technical failure or complication rates [84, 85]. A change in the direction of the needle (i.e. fanning the needle into the lesion) can also be obtained by torquing the scope, with results similar to those of the "classic" fanning technique [86, 87] (**Table 9s**). The fanning technique also seems equivalent to sampling using contrast-harmonic EUS guidance [13], but without requiring the additional cost of contrast.

Notably, all of the available studies included only pancreatic solid lesions, and the role of the fanning technique in non-pancreatic lesions has not been investigated. Intuitively, the



► **Video 2** Demonstration of the fanning technique. Online content viewable at: <https://doi.org/10.1055/a-2524-2596>

fanning technique is also supposed to acquire a sample more representative of the whole tumor, allowing an advantage even for molecular analyses, despite not yet being adequately investigated.

The panel then performed a meta-analysis of the four RCTs [84, 85, 86, 87] that compared fanning versus standard FNA/FNB and found a significant superiority of fanning for accuracy (RR 1.21, 95%CI 1.11–1.31) (**Fig. 5s**, part A), which was confirmed when excluding the torque technique (RR 1.27, 95%CI 1.16–1.38) (**Fig. 5s**, part B). The quality of evidence was downgraded owing to indirectness related to different sampling techniques (suction vs. no suction vs. slow pull) in the included RCTs (**Table 4s**). Therefore, a strong recommendation with a moderate quality of evidence was provided.

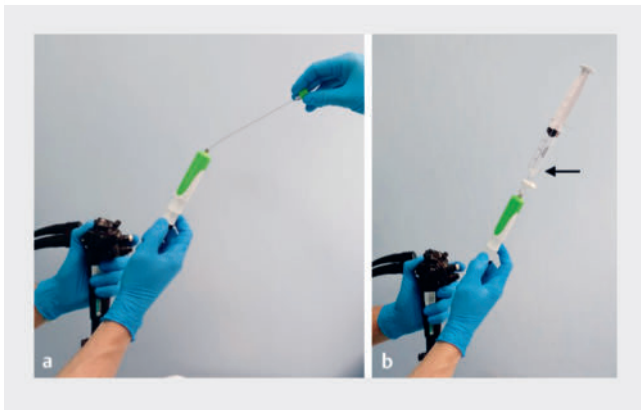
4.2 Aspiration techniques

RECOMMENDATION

ESGE recommends equally the wet-suction or slow-pull techniques for EUS-FNB of pancreatic masses because they provide high rates of adequate samples and tissue integrity, and reduce specimen bloodiness compared with dry suction. Strong recommendation, moderate quality of evidence.

Four main different aspiration techniques have been described: no-suction, slow-pull, dry-suction, and wet-suction techniques (including a modified wet-suction technique) (► **Fig. 2**). The no-suction technique just requires removal of the stylet before lesion puncture, with no application of negative pressure. The slow-pull technique consists of a slow retraction of the stylet while performing the to-and-fro movements within the lesion, which appears to apply low negative pressures to the needle tip. Suction techniques require removing the stylet and using a syringe with a 5-, 10-, or 20-mL negative pressure attached to the needle to provide a greater negative pressure than the slow-pull technique. The wet-suction technique also requires flushing of the needle with saline before performing the puncture to apply the negative pressure onto a fluid that has no expandability and, therefore, precisely transmits it to the tip of the needle [88].

Despite a wide literature on the topic, there is no striking evidence to suggest the unequivocal superiority of one suction technique over any another. Outcomes commonly evaluated in available studies were sample adequacy, cellularity, and tissue integrity/core procurement. Several meta-analyses showed that the wet-suction technique ranked as the best technique in terms of diagnostic accuracy [89, 90, 91]. Similarly, the wet-suction technique is ranked as the best technique regarding adequacy, followed equally by the slow-pull and dry-suction techniques, with the no-suction technique being inferior for this outcome. On the other hand, the no-suction and slow-pull techniques provided very low blood contamination compared with the wet-suction and dry-suction techniques [92, 93]. In addition, wet-suction seems better than the dry-suction tech-



► **Fig. 2** The different techniques for tissue sampling include: **a** the slow-pull technique, consisting of a slow retraction of the stylet while performing to-and-fro movements within the lesion, which appears to apply low negative pressures to the needle tip; **b** the wet-suction technique, which requires removal of the stylet and flushing of the needle with saline before performing the puncture so that, when negative pressure is applied to a fluid, which has no expandability, this is precisely transmitted to the tip of the needle.

nique regarding blood contamination. Notably, the impact of blood contamination has been inherited from FNA studies as it could impair cytologic evaluation. In contrast, it should not impact the assessment of histologic samples or the capability to retrieve high quality histologic tissue [94]. Furthermore, most studies evaluated only pancreatic solid lesions, with a few lymph nodes and submucosal tumors included, and subgroup analyses were not performed in the meta-analyses.

The panel updated the meta-analysis of RCTs comparing different techniques for tissue sampling with EUS-FNB of pancreatic solid lesions and found 10 RCTs [33,44,94,95,96,97,98,99,100,101] (**Table 10s**).

As outlined in a previous network meta-analysis [89], the no-suction technique was significantly inferior to the other techniques in terms of sample adequacy (RR 0.85, 95%CI 0.08–0.92 vs. slow pull; RR 0.85, 95%CI 0.78–0.92 vs. dry suction; RR 0.83, 95%CI 0.76–0.90 vs. modified wet suction), although it led to less blood contamination of samples. The highest tissue integrity was observed with modified wet suction (RR 1.36, 95%CI 1.06–1.75 vs. dry suction) and the highest rate of blood contamination was observed with dry suction (RR 1.44, 95%CI 1.15–1.80 vs. slow pull). Altogether, this evidence favors using the wet-suction technique, with the slow-pull technique considered a valuable alternative to be used intuitively for hypervascular pancreatic lesions or where cytologic evaluation is required. With any suction technique, it is recommended to neutralize residual negative pressure in the needle before withdrawing it from the target lesion to avoid contamination of the sample by GI fluid.

Data on nonpancreatic lesions are scarce. The trial by Crinò et al. found a higher rate of tissue core retrieval with the wet-suction rather than slow-pull technique in the subgroup of nonpancreatic lesions (67% vs. 48%), although the significance threshold (adjusted for multiplicity) was not reached, probably

because the RCT was underpowered for this subgroup analysis [94]. It is likely that the application of suction may have a greater impact on the quantity of tissue aspirated into the needle in softer tissues, such as nonpancreatic lesions, rather than stiff pancreatic masses, like adenocarcinoma.

The panel downgraded the quality of evidence to moderate owing to indirectness related to the different study designs and different FNB needles used in the individual studies (**Table 4s**). Therefore, a strong recommendation with a moderate quality of evidence was provided.

4.3 Number of to-and-fro movements

The number of to-and-fro movements, also called the “number of actuations,” is the number of back-and-forth movements performed inside a lesion within the same needle pass. Most studies reported performing 10–15 actuations, but only a few have specifically investigated this topic and only in pancreatic solid lesions, reporting scanty and heterogeneous data that are difficult to standardize.

An RCT comparing 40 versus 20 actuations performed with a 22G side-fenestrated needle showed no benefit in doing more movements [102]. A recent RCT performed with FNA needles demonstrated similar accuracy with 10, 15, and 20 actuations when suction was applied, but with higher blood contamination with 20; in contrast, 10 actuations were associated with lower accuracy if no suction was used [103]. The authors concluded that 10 or 15 to-and-fro movements should be performed with and without suction.

Two crossover RCTs using a 22G Franseen needle compared different numbers of actuations. The first study demonstrated a slightly, though not significantly, higher accuracy with 15 actuations compared with five; however, 15 actuations were better than five regarding the area of the tissue core retrieved [104]. Conversely, the second study demonstrated that three actuations provided similar results to 12 in terms of diagnostic accuracy and microscopic histologic quantity, but with less blood contamination [105].

Finally, a large retrospective study raised concerns about an increased risk of AEs when performing more than 15 actuations during EUS-FNA [106], although, considering its retrospective design, the results of this study should be interpreted with caution.

Given the paucity of data and the discordant results of the RCTs, which tested different numbers of actuations, thereby making it impossible to standardize the data, the panel decided to refrain from providing a statement on this topic. Intuitively, the number of actuations should also depend on the lesion size. In fact, each to-and-fro movement should ideally cross the entire diameter of the tumor. Consequently, in the case of small lesions, the range of movement would be very small, and increasing the number of actuations could result in a better sample. In contrast, the range of movement in large masses is extended, so allowing for a reduction in the number of to-and-fro movements.

4.4 Number of passes

RECOMMENDATION

ESGE recommends performing two passes with end-cutting FNB needles and three passes with reverse-bevel FNB needles. At least four passes are needed with FNA needles when ROSE is not available.

Strong recommendation, moderate quality of evidence.

Overall, several meta-analyses have demonstrated that, compared with FNA, FNB needles can reduce the number of passes required to achieve a diagnosis [21, 107, 108, 109, 110, 111]; however, most of the studies available in the literature reported the diagnostic yield of EUS-TA in relation to the cumulative number of passes or reported partial data on each pass outcome, and only a limited number of studies performed a per-pass analysis with a pre-established (or established on ROSE) number of passes [36, 45, 84, 96, 112, 113, 114, 115, 116, 117, 118, 119, 120, 121, 122]. Notably, most studies employing FNA needles used ROSE during EUS-guided sampling.

With the above-mentioned limitation, based on specifically designed studies, when ROSE is unavailable, to achieve a diagnostic yield of approximately 90%, four passes should be performed with an FNA needle and three with a reverse-bevel needle. With the advent of new end-cutting FNB needles, it seems that the number of required passes could be further lowered; in fact, when using 22G Franseen [122, 123] or fork-tip needles [36], two passes increased diagnostic yield compared with one and reached the plateau, thereby suggesting that two passes might be sufficient. A slight advantage of performing a third

pass was observed using 22G three-prong asymmetric tip [45] and 25G fork-tip needles [36].

These findings were also observed in a recent meta-analysis of 19 RCTs that demonstrated, using any FNB needle, a pooled diagnostic accuracy of 78% (95%CI 73%–84%), 87% (95%CI 83%–91%), 92% (95%CI 88%–95%), 89% (95%CI 81%–96%), and 96% (95%CI 95%–97%) with one, two, three, four, and five passes, respectively, with significant benefit for performing up to three passes. Subgroup analysis of end-cutting needles (Franseen and fork-tip) demonstrated a pooled accuracy of 80% (95%CI 74%–87%), 87% (95%CI 79%–94%), and 91% (95%CI 84%–97%) with one, two, and three passes, respectively, with no benefit from adding the third pass [124] (► **Table 3**).

Most of the reported studies included patients with pancreatic solid lesions; however, two to three passes with an end-cutting needle seem sufficient even for submucosal lesions and lymph nodes [73, 120].

The panel downgraded the quality of evidence to moderate owing to the indirectness related to different availability of ROSE/macrosopic on-site evaluation (MOSE) across the RCTs (**Table 4s**).

Finally, with the progressive advent of molecular analyses to aid personalized treatments and considering the need to also retrieve material for this precise aim, additional passes, apart from the diagnostic ones, could be considered. Although the aforementioned meta-analysis [124] found higher adequacy with three passes, even using end-cutting FNB needles, probably owing to the higher quality of tissue samples, promising data show that two passes are not different from three passes in terms of the quantity of retrieved DNA and RNA for molecular analyses [125]. Nonetheless, the standard technique for EUS-TA should also be established based on the center's and endoscopists' individual experiences, as most of the published

► **Table 3** Comparison of numbers of needle passes for tissue sampling of pancreatic masses.

Outcomes	Number of passes	Number of RCTs	Number of patients	OR (95%CI); I ²
Any FNB needle				
Diagnostic accuracy	Two vs. one	9	1159	1.9 (1.4–2.7); 50%
	Three vs. two	9	1159	1.6 (1.2–2.1); 0%
	Three vs. one	8	1045	3.2 (2.0–5.3); 61%
	Four vs. three	4	398	1.1 (0.7–1.8); 0%
Tissue adequacy	Two vs. one	6	1072	2.1 (1.6–2.8); 36%
	Three vs. two	5	962	1.9 (1.3–2.8); 61%
	Three vs. one	5	962	4.1 (2.9–5.9); 50%
End-cutting FNB needles				
Diagnostic accuracy	Two vs. one	6	674	1.8 (1.2–2.6); 0%
	Three vs. two	5	411	1.4 (0.9–2.2); 0%
Tissue adequacy	Two vs. one	4	434	2.2 (1.7–2.9); 0%
	Three vs. two	3	544	3.0 (2.0–4.5); 0%

FNB, fine-needle biopsy OR, odds ratio.

literature represents standards in high volume centers with experienced endosonographers and pathologists.

4.5 EUS-guided tissue acquisition in jaundiced patients needing biliary stenting

RECOMMENDATION

ESGE suggests performing EUS-TA before ERCP in jaundiced patients with pancreatic head lesions, particularly when self-expandable metal stents are being used. Conditional recommendation, low quality of evidence.

For patients with obstructive jaundice due to an unresectable pancreatic head tumor, given the concurrent need for cyto/histologic confirmation that is mandatory before chemotherapy, performing both the EUS and ERCP procedures during the same session may represent a valuable option. ERCP is however more widely available than EUS, and relieving bile duct obstruction is commonly considered more clinically urgent than tissue acquisition for establishing a pathologic diagnosis [126]. Therefore, in most instances, biliary stenting frequently precedes EUS-TA; however, some concerns have been raised regarding the impact of biliary stents on the diagnostic accuracy of EUS-TA, likely owing to poor visualization of the lesion from acoustic shadowing, reverberation, and/or surrounding inflammation associated with the stent [127, 128, 129]. Additionally, these studies seem to suggest that plastic or self-expandable metal stents (SEMSs) could have a dissimilar effect because of differences in their material and diameter.

Table 11s shows the data from the studies that have assessed the impact of the presence of a biliary stent on the diagnostic performance of EUS-FNA/FNB of masses in the pancreatic head [128, 129, 130, 131, 132, 133, 134]. As reported in the meta-analysis by Facciorusso et al. [135], only SEMSs showed an impact on decreasing the diagnostic accuracy of EUS-TA (OR 0.5, 95%CI 0.2–1.0), whereas plastic stents had no impact (OR 0.9, 95%CI 0.5–1.5), with the pooled accuracy of EUS-FNB after placement of a plastic stent around 85% [135]. Therefore, the panel concluded with a conditional recommendation, based on retrospective studies, in favor of performing EUS-TA before ERCP in patients with jaundice due to pancreatic head masses, particularly if SEMSs are to be used.

5 On site evaluation

5.1 Rapid on-site evaluation (ROSE)

RECOMMENDATION

ESGE recommends the use of ROSE when EUS-FNA is performed. ROSE is not needed for EUS-FNB, particularly with end-cutting needles, of pancreatic solid lesions and submucosal lesions. Strong recommendation, moderate quality of evidence.

ROSE is a cytomorphologic diagnostic procedure that allows assessment of the adequacy of the material obtained during individual biopsy passes within a few minutes, in or near to the endoscopy suite (on-site). Once the tissue has been acquired, the section obtained is printed onto a glass slide, stained, and observed under a microscope by the cytopathologist. The sampling is repeated until the cytopathologist deems the specimen obtained to be adequate [136].

ROSE may be performed by a cytopathologist, a pathology trainee, or a cytotechnologist. Given the low availability of these professional figures, training endosonographers to evaluate the specimen themselves has been proposed as a potential solution. In the prospective double-blind RCT by Savoy et al., well-trained endosonographers had inferior abilities compared with a cytopathologist in terms of identifying specimen adequacy ($P=0.004$) and making a preliminary estimate of malignancy ($P<0.001$) in various lesions (lymph nodes, pancreas, and liver specimens) [137]. In a more recent RCT, which exclusively analyzed pancreatic solid lesions, the sensitivity and accuracy of ROSE by the endosonographer for malignancy were high (93% and 88%, respectively), with a shorter procedural duration, as well as fewer needle passes in the ROSE versus non-ROSE group [138]. Zhang et al. compared ROSE performed by endoscopists in 97 patients to 97 patients without ROSE in a RCT [139]. Self-ROSE improved the diagnostic accuracy ($P<0.001$) and sensitivity ($P<0.001$) compared to the non-self-ROSE group, with an acceptable consistency between endoscopist and pathologist in the cytopathologic diagnosis ($P<0.05$) and in the sample adequacy rate ($P<0.001$) [139]. In the prospective study by Eloubeidi et al. [140], an excellent agreement between ROSE and the final cytology was demonstrated. Of the 300 lesions initially reported as malignant on ROSE, 294 (98%) remained malignant on the final cytology, while only 2% of the lesions initially reported as being benign on ROSE were upgraded to malignant or suspicious for malignancy in the final cytology report. Scant cellularity was the most frequently reported reason for discrepancies, followed by the need for consultation with other specialists, the need for ancillary studies, intraobserver variability, and challenging diagnoses [140].

Given the rapid advance of artificial intelligence (AI) in the medical field, Lin et al. [141] reported the validation of an AI-based model (ROSE-AI model) to substitute for manual ROSE during EUS-FNA; it demonstrated strong performance in

detecting cancer cells, achieving an accuracy rate of 83% in the internal validation dataset and a comparable result of 89% in the external validation dataset [141].

The cost-effectiveness of ROSE is still under debate. In the cost-analysis study by Wani et al. [142], EUS-FNB of pancreatic and nonpancreatic solid lesions appeared a more cost-effective strategy than EUS-FNA with ROSE. On the other hand, in a study aimed at assessing the cost-efficacy of ROSE performed during EUS-FNA of several different GI lesions, EUS-FNA with ROSE was associated with a significant cost-effectiveness benefit, resulting in savings of almost \$252 per case of EUS-FNA when ROSE was applied. The economic savings attributed to ROSE were owing to a lower rate of inadequate specimens and fewer EUS-FNA sessions needed to achieve the final pathologic diagnosis [143]. In a retrospective study by the same group, the cost-effectiveness analysis was not different between EUS-FNB and EUS-FNA with ROSE in GI lesions [144]. Therefore, the authors concluded that the choice of strategy depends on availability and local expertise.

As demonstrated in previous meta-analyses [145, 146], the inclusion of ROSE in EUS-FNA improves sample adequacy for pathologic evaluation and enhances the diagnostic performance of the procedure. In particular, the aforementioned network meta-analysis demonstrated that EUS-FNA with ROSE leads to similar diagnostic outcomes as compared with EUS-FNB, even with highly performing end-cutting needles, both in pancreatic solid lesions [27] and subepithelial lesions [62]. On the other hand, conflicting results are reported in the literature concerning EUS-FNA of lymph nodes [147].

ROSE may not be routinely and widely available; it is especially present in high volume tertiary care centers. In a global survey published in 2016 [148], ROSE was used by 98% of American endosonographers and only by 48% of European and 55% of Asian respondents.

As previously reported, the development of end-cutting FNB needles led to very high adequacy and accuracy rates, thereby limiting the need for ROSE, as outlined in several studies and in a large multicenter RCT enrolling 771 patients with solid pancreatic masses, which found comparable diagnostic accuracies (96% with ROSE and 97% without ROSE; $P=0.40$), but with a significantly shorter mean sampling procedural time (18 [SD 9] vs. 12 [SD 6] minutes; $P<0.001$) [149]. Similar results were also reported in the recent meta-analysis of eight studies (2147 patients), where the difference in terms of sample adequacy of solid pancreatic lesions was not statistically significant between EUS-FNB alone versus EUS-FNB +ROSE [150]. The diagnostic accuracy was superior in the EUS-FNB +ROSE group ($P=0.03$); however, when considering only the new FNB needles, this difference did not reach statistical significance ($P=0.56$). The same results were observed in the setting of subepithelial lesions, where the above network meta-analysis showed that ROSE did not improve the diagnostic yield of EUS-FNB [62].

Nowadays, with the advancement of digital imaging technology, there is the possibility of an expert cytopathologist evaluating FNA specimens remotely. In 2014 Khurana et al. demonstrated that telecytopathology on-site evaluation of EUS-FNA of pancreatic lesions reduced the nondiagnostic rate,

especially for solid lesions [151]. A more recent study by Machado et al. demonstrated the feasibility of a low-cost instant messenger smartphone application for evaluating specimens of EUS-FNA of pancreatic solid lesions in terms of sample adequacy, with the possibility of an initial diagnosis of malignancy in 61% of samples [152]. Telecytopathology offered by high volume centers may in the future serve as an effective substitute for on-site evaluation, overcoming the issue of a shortage of cytopathologists.

The studies comparing the diagnostic outcomes of EUS-FNB with ROSE versus EUS-FNB without ROSE are reported in **Table 12s** [79, 149, 153, 154, 155, 156, 157, 158].

As reported in the study by Facciorusso et al. [150], the meta-analysis of the two RCTs [79, 149] that compared the two approaches showed no difference (OR 1.1, 95%CI 0.3–3.9), with moderate evidence of heterogeneity ($I^2=49%$).

The high level of indirectness, related to the different study designs (one of the RCTs was a subanalysis of an RCT) and different FNB needles used, led to downgrading of the quality of evidence to moderate (**Table 4s**). Therefore, a strong recommendation with a moderate quality of evidence was provided.

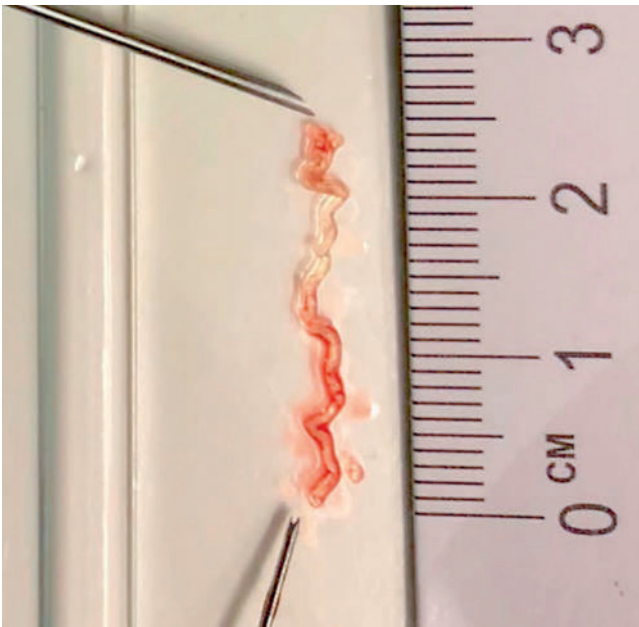
5.2 Macroscopic on-site evaluation (MOSE) and visual on-site evaluation (VOSE)

RECOMMENDATION

ESGE recommends the use of MOSE for EUS-FNB of pancreatic masses because this approach leads to high diagnostic accuracy, with the need for fewer needle passes. Strong recommendation, moderate quality of evidence.

Other techniques have been implemented for assessing the quality of tissue samples during EUS procedures. MOSE, introduced by Iwashita et al. [159], involves evaluating the presence of a macroscopically visible core (a whitish or yellowish tissue fragment) in the sample dispensed onto a glass slide; if it is ≥ 4 mm, it predicts the presence of a histologic core (**► Fig. 3**). MOSE has been evaluated with both FNA [160] and FNB needles [123], demonstrating excellent diagnostic parameters for both techniques. Moreover, according to a recent noninferiority RCT [123], MOSE can significantly reduce the number of needle passes in patients with pancreatic and nonpancreatic solid lesions, with an accuracy that is not inferior to that of EUS-FNB with three needle passes. Sundaram et al. showed that, when end-cutting EUS-FNB needles were used for the evaluation of solid pancreatic lesions, no difference in sensitivity, specificity, or diagnostic accuracy was detected between ROSE and MOSE [161].

Visual on-site evaluation (VOSE) might represent an easy alternative to MOSE, consisting of assessing the EUS sample fully expelled into a graduated formalin vial, which is shaken to better visualize the presence of a macroscopically visible core. In the prospective single-center study by Stigliano et al. [162], the endoscopist evaluated the presence of a macroscopic visible core, the color (white or red/mixed) and the blood contam-



► **Fig. 3** Macroscopic on-site evaluation (MOSE) involves evaluating for the presence of a macroscopically visible core (a whitish or yellowish tissue fragment) in the sample after it has been dispensed onto a glass slide.

ination; the authors found that a VOSE “red-mixed specimen” was associated with a higher probability of histologic adequacy.

VOSE and MOSE are quick and simple procedures performed by the endosonographer in the endoscopy room, without the need for other professional figures, making them highly cost-effective; however, in comparison with ROSE, they do not provide quality information or a preliminary diagnosis.

A recent meta-analysis by Mohan et al. showed a pooled accuracy of FNA and/or FNB specimens in yielding a pathologic diagnosis by MOSE of 91% (95%CI 89%–93%), pooled sensitivity of 92% (95%CI 89%–94%), and pooled specificity of 99% (95%CI 97%–100%), which was also confirmed in the subgroup analysis that was restricted to end-cutting FNB needles [163]. Based on the single RCT by Mangiavillano et al. [123], no difference was observed in terms of diagnostic accuracy between EUS-FNB with MOSE versus without MOSE (RR 1.02, 95%CI 0.95–1.10). The panel therefore decided to downgrade the quality of evidence owing to imprecision (wide 95%CI crossing unity and failure to reach the optimal information size) (**Table 4s**). Therefore, a strong recommendation with a moderate quality of evidence was provided.

Given the very limited published data on the use of VOSE, the panel decided to refrain from providing a statement on VOSE.

5.3 Digital confocal laser microscopy

Ex vivo fluorescence confocal laser microscopy (FCM) represents a new digital tool allowing for real-time microscopic assessment of fresh unfixed biologic specimens. Its main advantage, especially in the field of EUS-FNB, is the fact that it produces digital histologic images without any need for con-

ventional slide preparation. Its application could lead to shorter procedures, fewer needle passes, and a lower risk of AEs, while at the same time obviating the need for ROSE.

Currently, the VivaScope 2500M-G4 microscope (MAVIG GmbH, Munich, Germany) has been evaluated in a limited number of studies. Briefly, the specimen obtained after the first needle pass is placed directly in a dedicated scaffold and, after a minimum amount of preparation, is put between two dedicated microscope slides and placed in the imaging device that, using a dedicated algorithm, converts the acquired image information into colors that resemble hematoxylin and eosin (H&E) staining [164]. In a prospective study that enrolled 81 patients undergoing EUS-FNB of solid pancreatic lesions, FCM accurately predicted the adequacy of the tissue sample in 96% of the samples, while there was significant agreement between FCM evaluation and the final histologic assessment (Cohen’s *k* coefficient 0.95, 95%CI 0.89–1.01), with 100% sensitivity and 67% specificity [164].

In a more recent multicenter study, the validity of digital FCM was evaluated by comparing the interobserver agreement between FCM and standard histologic analysis [165]. The digital images from FCM and digitalized paired whole-slide images from 25 consecutive patients with pancreatic EUS-FNB were sent to 10 international expert pathologists, with a high interobserver agreement demonstrated (Cohen’s *k* 0.79, 95%CI 0.65–0.92) [165]. Based on these studies, FCM could be of value in improving the real-time assessment of pancreatic solid lesions, although the high costs limit its applicability currently.

6 Tissue acquisition for pancreatic cystic lesions

6.1 Cyst fluid cytology and molecular analysis

RECOMMENDATION

ESGE suggests the use of glucose level over carcino-embryonic antigen (CEA) in the cystic fluid for the diagnosis of pancreatic mucinous cysts.
Conditional recommendation, low quality of evidence.

Accurate diagnosis and risk stratification for the development of malignancy in pancreatic cystic lesions (PCLs) are challenging. An unacceptable number of patients with PCLs with worrisome features that, according to guidelines, should undergo surgical resection are eventually diagnosed with benign disease on final histologic examination of the resection specimen [166]. In order to avoid unnecessary surgery, effective methods to better diagnose and subclassify PCLs are highly warranted.

EUS characteristics alone are usually insufficient to make a diagnosis, but there are some occasions where they are relevant (e.g. classic features of a pseudocyst in the correct clinical circumstances). EUS alone is also accurate in identifying serous cystic neoplasms, especially when honeycombing is present in a lesion with clear noncommunication with the pancreatic duct.

For most other lesions, there will be a need for sampling of the most suspicious aspect of the cyst, such as a mass or nodule, and this should be conducted as for a solid lesion. For those lesions without a clear suspicious target but where sampling has been deemed necessary, direct sampling is performed from fluid within the cyst. The use of adjunctive devices such as confocal microscopy and through-the-needle biopsy (TTNB) forceps are discussed separately.

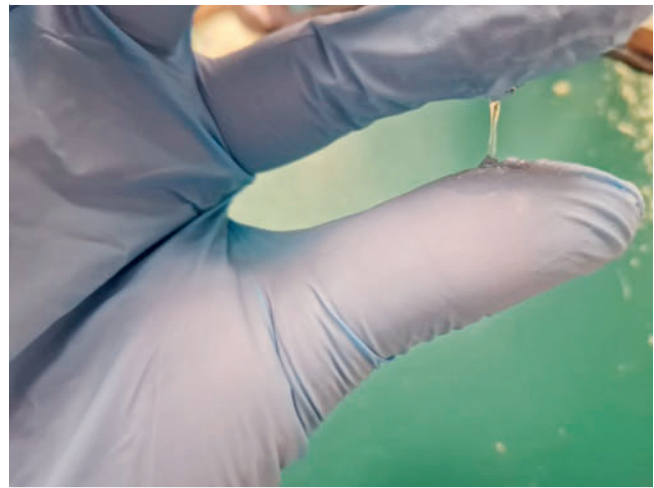
The technique involves using a standard FNA needle, as opposed to a biopsy needle, and most operators prefer either a 22G or 19G FNA needle. If a mucinous cyst is suspected, then a 19G needle is preferable, as the fluid can be very thick and requires a large needle channel for successful aspiration; however, 19G needles are more challenging in areas such as the uncinata process. If possible, the whole cyst should be aspirated to dryness in a single pass but, in multiloculated lesions, targeting of the largest cystic component and full aspiration is acceptable.

The needle should be positioned in the center of the cyst and the tip observed during aspiration to prevent contact with the cyst wall as it collapses. This should ensure complete aspiration and reduces any abrasion of the cyst wall by the tip of the needle. EUS-guided cyst FNA is low risk, but AEs such as bleeding, infection, cyst rupture, and pancreatitis have all been described. The overall risk was reported to be between 2% and 6% in a previous meta-analysis [167].

Cyst fluid assessment is comprised of its descriptive appearance and measurement of various components of the fluid, with the most common being cytology, and levels of carcinoembryonic antigen (CEA), amylase, and glucose. Few studies have examined the value of the cyst fluid appearance, although most endosonographers give a subjective description of the fluid viscosity at aspiration. The most objective measure of this is the “string sign,” which involves placing a droplet of the aspirate between the thumb and index finger of a gloved hand and then separating the fingers (► Fig. 4). A positive string sign is where the “string” stretches to 1 cm and persists for >1 second [168]. This has been assessed prospectively and is specific, but not very sensitive [169].

Several tumor markers have been investigated to try to determine which cystic lesions are more likely to be mucinous, as well as those at highest risk of malignant transformation. Initial studies showed the most accurate results using CEA, and a cutoff of 192 ng/mL gave an area under the curve (AUC) of 0.79 [170]. More recent studies have shown that lower levels of CEA in the aspirate may be more accurate [171, 172]. One of the biggest issues is the lack of use of a standardized assay for measurement in different institutions, leading to the variance in the accuracy for the different reported cutoffs. It is worth noting that high CEA levels have also been found in inflammatory cysts [172].

Measurement of the cyst fluid amylase is a potentially useful adjunct. A raised amylase level suggests communication of the cyst with the pancreatic duct, with levels <250 U/L largely excluding pseudocysts [173]. A highly elevated amylase level is associated with pseudocysts, but has also been seen in mucinous lesions [172].



► **Fig. 4** The string sign is shown during endoscopic ultrasound-guided fine-needle aspiration of a pancreatic cystic lesion. This test involves placing a droplet of the aspirate between the thumb and index finger of a gloved hand and then separating the fingers. A positive string sign is where the “string” stretches to 1 cm and persists for >1 second.

More recently there has been interest in inexpensive, widely available markers that might reflect the level of metabolic activity within a cystic lesion. In initial studies, a lower glucose level in the cyst fluid aspirate was reported to have a high sensitivity for diagnosing mucinous cysts, whether sent to the laboratory or performed using point-of-care glucometers [174]. A recent meta-analysis showed that a cyst fluid glucose level <50 mg/dL had a sensitivity of 91% and specificity of 91% when sent to the laboratory and 90% and 84%, respectively, when using point-of-care glucometers [175]. There are two studies that have examined the utility of combining glucose and CEA levels, with one showing improved accuracy [176] and the other showing no additional benefit of CEA over glucose alone [177]. A more recent study examined the lactate level within cyst aspirates and showed significantly lower levels in mucinous cysts. Glucose had superior operating characteristics to both CEA and lactate in this study [178].

Examination of the cellular content in a pancreatic cyst aspirate is perhaps one of the oldest methods used to try to determine the nature of the lesion. The sensitivity of cyst fluid cytology is generally poor owing to the low cellular yield in the fluid aspirate. One meta-analysis showed a pooled sensitivity of 63% (95%CI 56%–70%) and a specificity of 88% (95%CI 83%–93%) [179]. This was also reflected in the high positive likelihood ratio (4.5) and low negative likelihood ratio (0.5). This means that cytology is only reliable if a positive diagnosis is made as false positives, especially for advanced changes, are uncommon, but negative cytology cannot currently exclude a mucinous lesion or even malignancy.

Within a pancreatic cyst fluid aspirate, there are other sources of information that are currently being investigated. These include assessment for the presence of genetic mutations, such as *KRAS* and *GNAS*, which appear to have a high specificity for

mucinous cysts [180]. Other studies have used next-generation sequencing to create a genetic profile for the cyst, combining the presence of different gene mutations [180]. Differing expression of mucin proteins in proteomic studies has suggested higher risk patterns, but this needs confirmation. Similarly, exploration of proteomics, metabolomics, and the microbiome may improve the accuracy of fluid sampling [181]. These areas are not currently widely available clinically and remain within the realm of exploratory research. **Table 13s** shows the outcomes of seven meta-analyses published in the last 5 years [175, 177, 182, 183, 184, 185, 186].

Glucose level showed similar specificity and significantly higher sensitivity as compared with CEA; molecular analyses led to very good results, but the high costs and the limited availability represent major concerns with their use. Therefore, a weak recommendation, with a low quality of evidence, in favor of the use of glucose levels was provided, because it was based on nonrandomized studies. The use of CEA might have a complimentary role, although whether their combined use would increase significantly the diagnostic accuracy is still uncertain.

6.2 Through-the-needle biopsy (TTNB)

RECOMMENDATION

ESGE suggests EUS-TTNB where the histologic diagnosis may change the clinical management of the patient. TTNB should be avoided in PCLs with communication with the pancreatic duct owing to the risk of serious AEs. Conditional recommendation, very low quality of evidence.

TTNB is performed by a new device that enables retrieval of histologic tissue, comprising epithelium and stroma, from the cystic wall or septa [187]. The through-the-needle microforceps biopsy technique has shown promising results for the diagnosis and subclassification of pancreatic cysts, enabling immunohistochemical, as well as high quality molecular diagnostic examination, far more accurately when compared with EUS-FNA [188, 189, 190, 191]. Moreover, a good interobserver agreement among pathologists has been demonstrated [192].

There are currently two commercially available devices: the Moray Micro forceps (US Endoscopy, Mentor, Ohio, USA) and the Micro Bite forceps (MTW Endoskopie Manufaktur, Germany), with the former most extensively tested in the published studies.

The Moray Micro forceps has a length of 230 cm, a sheath diameter of 0.8 mm, and a jaw opening width of 4.3 mm [193]. The single-use biopsy forceps can be passed through a standard 19G FNA needle. The jaws of the forceps are flat with multiple sharp teeth. The micro forceps can either be preloaded in the needle or introduced after the cyst has been punctured by a 19G needle and the stylet removed. When the transducer is positioned in the second part of the duodenum with the endoscope tip flexed, it may be difficult to advance the micro biopsy forceps through the needle owing to resistance from within a

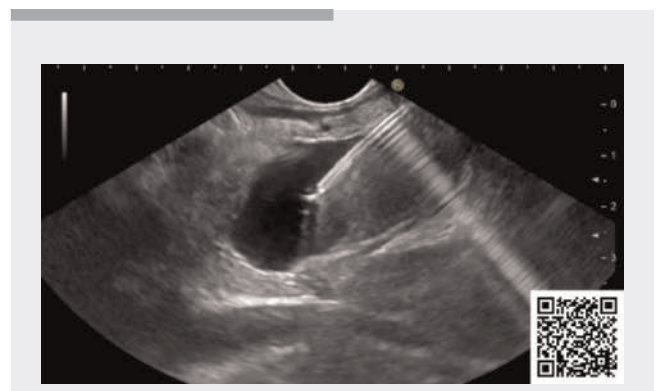
bent needle. If resistance is experienced, slight, repetitive, gentle opening and closing of the forceps during introduction through the needle reduces the friction and often helps overcome this problem. In addition, aspirating some of the fluid before TTNB ensures an amount of “nonblood-contaminated” fluid, as some minor bleeding is often observed after TTNB. Moreover, the fluid aspiration reduces the cystic wall tension and may facilitate grabbing tissue into the jaws of the microforceps [194]. Following cyst puncture and forceps introduction, the jaws of the forceps are easily visualized under real-time EUS guidance. The jaws are opened, and the forceps advanced anteriorly to the needle tip to touch the cyst wall. The forceps should then be closed, while maintaining a slight pressure, and then retracted, while showing “tenting” of the wall lining. Observed “tenting” of the wall lining on EUS is usually a good predictor of an adequate sample; if this tenting effect is not experienced, the procedure should be repeated until the desired effect is seen or alternatively until clear resistance is felt when the biopsy forceps is retracted (► **Video 3**).

The tissue obtained should be visually inspected and the procedure repeated until at least two optimal biopsies have been acquired. It has been shown that extraction of more than two biopsies does not increase the sensitivity, but raises the risk of AEs [195].

The endoscopist should be aware of the risks associated with the procedure and try to minimize the intracystic needle time after obtaining an adequate number of samples. Following the retraction of the instruments, the lesion and the surrounding area should be re-examined to exclude any AEs, such as intracystic hemorrhage, although the latter is self-limited in almost all cases.

After retraction of the micro biopsy forceps, the small specimen is placed onto a small paper disc and finally introduced into a cassette [196].

According to the recently published evidence-based international Kyoto guidelines [15], there are no established indications for EUS-TTNB, and it seems too early to reach any definitive conclusions. It was demonstrated that TTNBs can substantially change the clinical management strategy in patients with



► **Video 3** Demonstration of the “tenting effect” during through-the-needle biopsy.

Online content viewable at:
<https://doi.org/10.1055/a-2524-2596>

PCLs in 12%–19% of cases, mostly by providing the diagnosis of a serous cyst adenoma in an oligocystic or unilocular cyst, and so leading to discontinuation of follow-up [188]. As a general principle, EUS-TTNB should be performed only in patients who are fit for surgery, with a clear indication for biopsy, and where the biopsy diagnosis may change the clinical management of the patient [15].

Because EUS-TTNB offers the chance to evaluate a micro-histologic sample of the cyst wall, the key advantage of the procedure is gained when the histotype of the cyst is unknown, as typically happens in the case of unilocular/oligocystic PCLs. This cyst “morphology” may encompass a wide spectrum of PCLs, ranging from the more common intraductal papillary mucinous neoplasia (IPMN), serous cystadenoma, or mucinous cystadenoma to more rare conditions, including NETs [197, 198] or schwannomas [199, 200].

The accurate definition of a PCL is crucial for the management of the patient as, for example, large mucinous cysts, unlike serous cystadenomas, are frequently indicated for resection. In contrast, whether EUS-TTNB will play a role in the evaluation of a PCL’s dysplasia grade remains doubtful. In fact, as a general principle, biopsy is not the way to define the grade of dysplasia because of its variability within the same lesion and its patchy distribution along the cystic wall, thereby producing a risk of a false-negative result owing to inadequate sampling [201].

Several meta-analyses have reported very high technical success rates of 90% and 100% for TTNB, and high sensitivity and specificity of around 80%, which are superior to standard FNA cytology [202, 203, 204].

Limiting factors include the lack of epithelium in non-mucinous cysts, but also denudation of the cyst wall, which may yield false-negative results. Moreover, as previously commented, the evaluation of dysplasia warrants cautious interpretation as the biopsies represent only a portion of the cyst wall and the results may be falsely negative. Therefore, any high risk features, such as a thickened cyst wall, nodules, or solid parts, should be targeted if possible.

AEs associated with the procedure range from 2% to 23%, and the rate seems higher compared with the standard EUS-FNA procedure [205, 206]. The most common AE reported is intracystic hemorrhage, which is defined as hyperechoic changes in the cystic lumen following the tissue acquisition; however, all published cases have been mild and, in most cases, without any clinical implications [207]. Infections are rarely seen after EUS-TTNB of pancreatic cysts and a multicenter, retrospective, propensity-score matched study demonstrated that antibiotic prophylaxis does not influence the infection rate, which appears to be very low [208]. EUS-TTNB can also cause acute pancreatitis, probably owing to destruction of the cyst wall, edema of the adjacent normal pancreatic tissue architecture, microclot passage into the main pancreatic duct, and leakage of the pancreatic juice. In a recently published meta-analysis, the pooled AE rate for pancreatitis was shown to be around 3% (95%CI 1.8%–4.5%) [207]. Most pancreatitis events had a mild clinical course; however, the reported rate of serious AEs was around 1.1% (95%CI 0.4%–2.7%), mainly due to severe pancrea-

titis [202]. Serious concerns about the use of TTNB were raised by a prospective Danish study that reported an AE rate of 10%, including a case of death due to post-TTNB pancreatitis [188].

A large multicenter publication that included 506 patients found age (OR 1.3, 95%CI 1.1–2.1), number of TTNB passes (from OR 2.2 [95%CI 1.3–4.3] to OR 3.2 [95%CI 2.0–6.3] with increasing number of passes), complete aspiration of the cyst (OR 0.6, 95%CI 0.3–1.0), and diagnosis of IPMN (OR 4.2, 95%CI 2.3–7.7) to be independent predictors of AEs [209]. No preventive measures have been clearly demonstrated to reduce the risk of pancreatitis, although Kovacevic et al. observed a decreasing trend in the incidence of pancreatitis when using prophylactic rectal indomethacin/diclofenac [188]. Future studies are needed to evaluate the role of rectal nonsteroidal anti-inflammatory drugs (NSAIDs) or aggressive hydration in minimizing the risk of pancreatitis after TTNB.

Table 14s reports the available meta-analyses assessing TTNB performance in patients with PCLs [202, 203, 204, 205, 206, 207, 210]. In all of these studies, TTNB clearly outperformed cytology in terms of diagnostic accuracy (ORs ranging from 3.4 [95%CI 1.3–9.0] to 9.4 [5.7–15.4]). Moreover, a recent network meta-analysis of retrospective studies found TTNB to be the best technique to differentiate mucinous cysts and to identify the malignant nature of a PCL (superiority index 13, 95%CI 5–17) [211].

The panel provided a conditional recommendation with a very low quality of evidence favoring the use of TTNB in PCL patients, because the evidence was based only on retrospective studies and owing to the high risk of imprecision (failure to reach the optimal information size) (**Table 4s**).

6.3 Confocal laser endomicroscopy

RECOMMENDATION

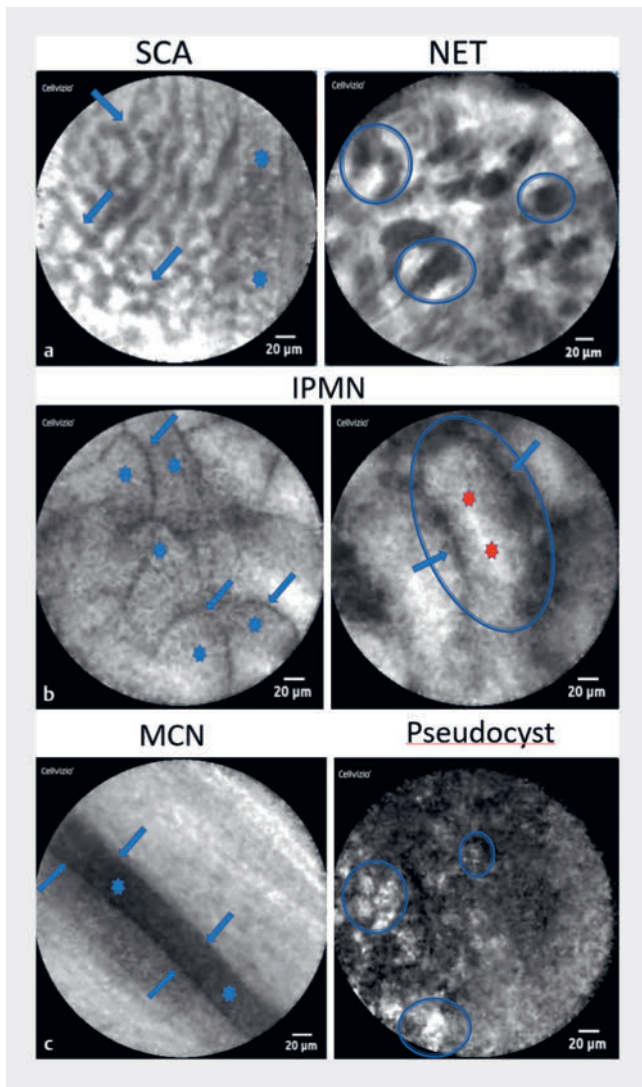
ESGE suggests the use of needle-based confocal laser endomicroscopy (nCLE) to discriminate between mucinous and non-mucinous pancreatic cysts in centers with adequate expertise.

Conditional recommendation, low quality of evidence.

Over the last decade, needle-based confocal laser endomicroscopy (nCLE) has emerged as a promising technology to overcome the limitations of EUS-FNA in the characterization of PCLs. nCLE enables real-time imaging of tissue and vascular structures.

Cellvizio I.V.E. (Mauna Kea Company, Paris, France) is a confocal laser imaging device adapted for imaging through a bundle of optical fibers, assembled with other miniaturized elements, called a Confocal Miniprobe, to allow real-time imaging of the internal microstructure of tissues (► **Fig. 5**).

Prior to each procedure, the AQ-Flex probe is inserted into the 19G FNA needle in lieu of the stylet and advanced until the probe is positioned with the tip aligned 1 mm beyond the needle tip and then secured with a special locking device. After EUS-guided puncture, the FNA needle should be carefully posi-



► **Fig. 5** Appearances of some of the different patterns observed during needle confocal laser endomicroscopy of pancreatic cystic lesions. **a** A serous cystadenoma (SCA), with the superficial vascular network seen as multiple interconnected black vessels (arrows) and big vessels (stars), in which moving red cells (small black points) are seen moving in the fluorescein-filled vessel, which appears white, and neuroendocrine tumor (NET) with irregular clusters of dark cells (blue ovals). **b** A pancreatic intraductal papillary mucinous neoplasia (IPMN) contains small papillary projections (stars) and one large papilla (blue oval) with a vascular core (red star), and the visible epithelial border (arrows). **c** A mucinous cystadenoma (MCN) with the epithelial border (blue star) and its limits marked (arrows), and a pancreatic pseudocyst, with inflammatory cells that can be seen moving in the liquid (blue ovals).

tioned within the cyst. A soft contact between the nCLE probe and the epithelium of the cyst is necessary to obtain relevant images. After image acquisition, fluid aspiration for cytology, tumor markers, and/or DNA, and/or TTNB can be performed.

Based on expert opinion, it can be recommended to minimize catheter manipulation and to stop the examination as soon as specific nCLE criteria are observed, and systematically when the potentially examinable area inside the cyst has been checked. The recommended imaging time is <10 minutes (ideally <6 minutes) to decrease the risk of pancreatitis [212].

Some concerns were previously raised concerning the reproducibility of nCLE results [213]; however, three other studies conducted with blinded reviewers reported an almost perfect interobserver agreement (>0.60) for mucinous lesions, serous cystadenomas, and pseudocysts [214, 215, 216]. Intraobserver reliability was addressed by two trials using the INDEX-study population [215, 216] and was reported for all nCLE criteria as substantial, kappa ranging from 0.68 to 0.78, for nCLE-naïve blinded reviewers (n=6) and as almost perfect, kappa ranging from 0.85 to 0.91, among six blinded nCLE experts (experience >30 nCLE cases) [216].

The main AE reported in the studies was post-procedural acute pancreatitis (with only one severe case reported). The highest rate was reported in the DETECT study (7%), which combined Spyglass cystoscopy and nCLE imaging in the same procedure [217]. These rates are comparable to the pooled pancreatitis rate of 1.6% (95%CI 0.6%–3.8%) and global AE pooled rate of 5.5% (95%CI 0.9%–13.6%) associated with EUS-guided FNA for PCLs performed using a 19G needle [167].

A French health economic evaluation of nCLE for the diagnosis of PCLs showed nCLE to be cost-effective for the therapeutic management of PCLs for serous cystadenoma [218]. This analysis showed that the addition of nCLE to EUS-FNA resulted in a reduction of 23% in the total rate of surgical intervention, which translated to a reduction in clinical costs of 13% [218].

Table 15s reports the data of five meta-analyses that assessed the diagnostic performance of nCLE in patients with PCLs [206, 219, 220, 221, 222]. The pooled sensitivity and specificity ranged between 82% and 90%, and 91% and 99%, respectively, with a reported pooled AE rate ranging from 1% to 5%, mostly due to pancreatitis. As reported in the meta-analysis by Facciorusso et al. [219], the OR for diagnostic accuracy of nCLE compared with EUS-FNA was 3.9 (95%CI 1.6–9.8). The aforementioned network meta-analysis [211] concluded that, for centers with relevant expertise and facilities, EUS-guided nCLE and EUS-guided TTNB are better choices for the diagnosis of PCLs (OR 88 [95%CI 29–214] and OR 40 [95%CI 11–104], respectively). Moreover, the indirect comparison between the two procedures reported in the meta-analysis by Kovacevic et al. [206] showed a slightly higher diagnostic yield with nCLE. Therefore, a conditional recommendation with a low quality of evidence was provided in favor of the use of nCLE, because it was based on nonrandomized studies.

7 Antibiotic prophylaxis

RECOMMENDATION

ESGE does not recommend the use of antibiotic prophylaxis before EUS-guided tissue sampling of solid masses and EUS-FNA of PCLs.

Strong recommendation, moderate quality of evidence.

Whether antibiotic prophylaxis should be administered prior to EUS-guided tissue sampling remains controversial. Incidence rates of bacteremia are reported to be low after EUS, with or without FNA, of cystic or solid lesions along the upper GI tract and for solid rectal lesions [223].

The American Society of Gastrointestinal Endoscopy (ASGE) published a guideline on antibiotic prophylaxis for GI endoscopy in 2015 that recommended against prophylaxis for solid lesions, while prophylaxis for EUS-guided sampling of cystic lesions (both pancreatic and mediastinal) was still recommended [223]. In 2017, the ESGE published a technical guideline on EUS-guided tissue sampling, confirming the indication for antibiotic prophylaxis for PCLs only, but with a low quality of evidence [1].

Over the past years, new evidence regarding antibiotic prophylaxis for EUS-guided tissue sampling of pancreatic cysts has been published. In 2020, Colan-Hernandez et al. published a randomized, noninferiority, double-blind, placebo-controlled clinical trial investigating whether EUS-FNA of pancreatic cysts without antibiotic prophylaxis increased the infection rate as compared with EUS-FNA with antibiotic prophylaxis [224]. They found that the risk of infections related to the procedure was overall very low (<1%) and was not increased when antibiotic prophylaxis was not used (OR 0.3, 95%CI 0.01–8.3) [224]. This finding was confirmed by two systematic reviews and meta-analyses, including six studies (the RCT and five retrospective series), which confirmed the very low incidence of infectious AEs (<1%), with no difference between the two groups [225,226]. **Table 16s** reports the studies comparing antibiotic prophylaxis versus no prophylaxis before EUS-FNA of PCLs [106,224,227,228,229,230].

Based on the available evidence, the panel recommended against the use of antibiotic prophylaxis in patients with PCLs undergoing EUS-guided sampling with complete aspiration of the cyst. A strong recommendation with a moderate quality of evidence was provided because of the risk of imprecision (wide CIs crossing unity and failure to reach the optimal information size) (**Table 4s**).

Very limited evidence is available about TTNB and the indication for prophylactic antibiotics. A retrospective propensity score-matched study reported one infectious event (1%) in the antibiotic prophylaxis group versus 2% in the control group [208]. Despite this preliminary evidence, further studies are needed to provide a definitive statement on the need for antibiotic prophylaxis before TTNB of PCLs.

8 Specimen handling and processing

Techniques used to process EUS-guided samples include conventional smears, cytospins, liquid-based cytology (LBC), and formalin-fixed paraffin-embedded tissue (specifically, cell blocks and biopsies). Cytologic methods (conventional smears, cytospins, and LBC) assess individual cells or clusters of cells, whereas histology (cell blocks and biopsies) allows assessment of intact fragments of tissue, including the architectural arrangements of cells and their relationship to surrounding tissues.

The technique of choice varies upon the nature of the lesion (solid or cystic), the type of needle used (FNA or FNB needle), the need to perform ROSE during the procedure, and the practical experience and expertise of the involved pathology personnel.

For solid lesions or for mural nodules of cystic lesions, the specimen obtained with an FNA needle can be partly spread onto glass slides (conventional smears) and partly collected in a vial containing saline or fixative. Glass slides must be fixed immediately by spray fixation or immersion in 95% alcohol for Papanicolaou or H&E staining; alternatively, they can be allowed to dry for Giemsa or Diff quick stain if ROSE is required. If ROSE is not required, the entire sample can be collected in the vial without conventional smear preparations. If the sample is collected fresh in saline solution, it should be rapidly transported to the laboratory and prepared to limit cell degeneration.

Whatever the medium, in the pathology laboratory, macroscopically visible tissue fragments and blood clots measuring >2 mm must be removed and processed separately in a paraffin block as a conventional biopsy, which requires formalin fixation. The remaining sample or its entirety, if no tissue fragments or blood clots are present, can be processed as LBC and/or cell blocks, the former technique requiring alcohol-based fixation, the latter 10% buffered formalin.

Alcohol-based fixatives are indicated for LBC (the two most common types being Cytolyt for ThinPrep and Cytorich Red for SurePath), which markedly attenuate the background elements, such as blood, mucus, and necrosis, but guarantee perfect cellular details. The residual LBC specimen can also be processed as a cell block, with subsequent formalin fixation.

To obtain a cell block, the sample is spun down with a centrifuge and the cellular material is concentrated into a cell button that is agglutinated and then processed as a routine histology specimen. There are several methods of agglutinating the cell pellet for embedding, the choice depending on which technique is available in the laboratory [231]. Sometimes no agglutination is necessary when large, clotted material is acquired with an FNA needle.

When using an FNB needle, the sample is generally corpusculated with macroscopically visible tissue fragments that can be collected in formalin and processed as a conventional histologic biopsy, even if there can be differences among the various needle sizes and types in term of specimen volume [232]. If tissue fragments are not visible or are very small (e.g. ≤2 mm), a cell block technique can be employed to avoid loss of material.

If ROSE is required, instead of smearing part of the sample onto glass slides, touch-imprint cytology can be performed [233]: tissue fragments are gently pushed and partially spread between two glass slides to avoid smashing, in this way slides suitable for cytologic examination are obtained. Tissue fragments should then be picked up and collected in formalin.

For cystic lesions, even if ROSE is not indicated, the liquid sample can be smeared onto glass slides (see above), especially if it is viscous/mucinous, or it can be entirely collected fresh and sent immediately to the pathology laboratory, where it can be processed undiluted with the cytopsin technique. This is a cell concentration method using centrifugal force to isolate, concentrate, and deposit a monolayer of cells onto a circular area on a slide. Cytopsin preparations maintain the background, such as necrotic debris and mucin, but samples that have undergone transportation stress, such as exposure to abnormally high or low temperatures, may yield poor quality cells with low overall viability. Alternatively, the liquid sample can be collected in an alcohol-based fixative for LBC or in 10% buffered formalin for cell block preparation.

When dealing with pancreatic cyst fluid, the liquid should be triaged according to its quantity. Triage of aspirated PCLs requires an integrated multidisciplinary approach that involves clinical evaluation, radiologic assessment, cyst fluid biochemistry, and molecular/genetic testing, as well as cytologic evaluation. In general, if it is ≤ 0.5 mL, it is sent fresh for biochemical analysis or collected in ethanol for molecular studies, avoiding cytologic examination. If > 0.5 mL, an aliquot of fluid can be submitted for cytologic examination and processed as described above. Each ancillary test requires at least 0.3 mL [234]. An EUS-TTNB will be processed as a standard histology specimen.

All of cytopsin, conventional smears, and LBC, as well as formalin-fixed paraffin-embedded tissue (cell blocks and biopsies) allow for further studies (immunohistochemical stains and molecular analysis), although cell blocks and any biopsies, which have been formalin fixed, are considered optimal for immunohistochemistry and additionally allow direct comparison of the same cells between multiple analyses [235, 236].

Regarding processing techniques for EUS-FNA samples, the superiority of LBC over conventional smears is controversial; however, as shown in a recent meta-analysis [237], combining LBC with conventional smears showed a significantly higher pooled sensitivity compared with conventional smears alone and LBC alone for the clinical evaluation of pancreatic lesions. The combination of LBC and cell blocks has also been shown to significantly improve diagnostic accuracy, indicating that these specimen processing techniques complement each other [238].

With regard to solid lesions around the digestive tract, as demonstrated in the study by Huang et al. [239], the combination of cytologic and histologic specimen processing methods also contributes additional diagnostic efficacy to EUS-FNA in solid lesions of the digestive tract. As for PCLs, it was demonstrated that the diagnostic yield of an EUS-FNA sample improved when the endosonographer processed the specimen by spreading it onto glass slides, instead of collecting it directly

into the liquid medium for LBC [240]; in contrast, with regards to the presence of mucus, cell block assessment appears superior to direct smears [241].

With regard to genomic analysis, there is limited literature on sample adequacy for molecular testing and genomic sequencing for pancreatic ductal adenocarcinoma obtained via EUS-FNA versus EUS-FNB. Comprehensive genomic profiling using next-generation sequencing has become an approved diagnostic test and has been successfully performed on FNA and FNB samples, including cell blocks, in several smaller studies [242, 243, 244]. Tumor surface area and tumor cellularity are essential parameters in determining sample adequacy for molecular testing: up to 2000 cells and 30% tumor cellularity may be necessary to perform comprehensive genomic analysis, but analysis can be successful at $< 10\%$ tumor cellularity [243]. Mohamad et al. found that FNB was more likely to result in sufficient tissue sampling for genomic and molecular testing [245]. They demonstrated that sample adequacy for molecular testing was achieved in 71% of patients who underwent FNB compared with 32% of patients who underwent FNA ($P < 0.001$).

In the absence of exact guidelines for material processing, each institution should thoroughly evaluate the optimal preparation method of EUS-FNA/FNB samples, considering that pathologists must fill the gap between the high technology endosonographer apparatus and the low/no technology sample preparation tools that they use [246]. Consequently, collaboration between endoscopists and pathologists is critical for success, with an understanding that cytologic and histologic processing techniques often complement each other, but tissue pieces > 2 mm need to be processed for histology. Sample processing techniques should be selected according to an individual center's experience and expertise, bearing in mind that samples processed histologically are optimal for immunohistochemistry, are more likely to be adequate for molecular analyses, and may be necessary to make certain diagnoses requiring intact tissue architecture.

Disclaimer

ESGE Technical and Technology Reviews represent a consensus of best practice based on the available evidence at the time of preparation. They may not apply in all situations and should be interpreted case by case in the light of specific clinical situations and resource availability. Further controlled clinical studies may be needed to clarify aspects of the statements, particularly in the absence of high quality of evidence, and revision may be necessary as new data appear.

ESGE Technical and Technology Reviews are intended to be an educational device to provide information that may assist endoscopists in providing care to patients. They are not rules and should not be construed as establishing a legal standard of care or as encouraging, advocating, requiring, or discouraging any treatment.

Acknowledgement

We thank Professors Andrea Anderloni and Jayanta Samanta for their thorough revision of the draft of this manuscript.

Conflict of Interest

L. Archibugi has received consultancy fees from Boston Scientific (2024). M. Arvanitakis has provided consultancy and received support for courses from Pentax and Boston Scientific (both 2024 to present). S. Carrara has received consultancy fees from Olympus and Boston Scientific (both 2022 to 2024). C. Fabbri has provided consultancy to Boston Scientific (2020 to present) and Steris (2024). J. Iglesias-Garcia has received speaker's and advisor fees from Fujifilm (2022 to present), Boston Scientific (2016 to present), and Medi-Globe (2021 to present). J. Leeds has received speaker's and advisor fees from Medtronic, Boston Scientific, Olympus, and Viatrix (2015 to present); course support from Boston Scientific, Medtronic, Olympus, and Cook Medical (2018 to present); he is Secretary of the Pancreatic Society of Great Britain and Ireland (2022 to present). B. Napoleon has received fees for teaching from Olympus, Boston Scientific, and MunaKea (all 2018 to present). P. Vilmann has provided consultancy to Medi-Globe (1992 to present). S.F. Crinò, J. Dhar, A. Facciorusso, A. Fornelli, L. Fuccio, P. Gkolfakis, B. Haugk, I.S. Papanikolaou, A. Seicean, P.M.C. Stassen, and T.C. Tham declare that they have no conflict of interest.

References

- [1] Polkowski M, Jenssen C, Kaye P et al. Technical aspects of endoscopic ultrasound (EUS)-guided sampling in gastroenterology: European Society of Gastrointestinal Endoscopy (ESGE) Technical Guideline – March 2017. *Endoscopy* 2017; 49: 989–1006 doi:10.1055/s-0043-119219
- [2] Pouw RE, Barret M, Biermann K et al. Endoscopic tissue sampling – Part 1: Upper gastrointestinal and hepatopancreatobiliary tracts. European Society of Gastrointestinal Endoscopy (ESGE) Guideline. *Endoscopy* 2021; 53: 1174–1188 doi:10.1055/a-1611-5091
- [3] Badaoui A, Teles de Campos S, Fusaroli P et al. Curriculum for diagnostic endoscopic ultrasound training in Europe: European Society of Gastrointestinal Endoscopy (ESGE) Position Statement. *Endoscopy* 2024; 56: 222–240
- [4] Guyatt G, Oxman AD, Akl EA et al. GRADE guidelines: 1. Introduction–GRADE evidence profiles and summary of findings tables. *J Clin Epidemiol* 2011; 64: 383–394 doi:10.1016/j.jclinepi.2010.04.026
- [5] Crino SF, Brandolese A, Vieceli F et al. Endoscopic ultrasound features associated with malignancy and aggressiveness of nonhypovascular solid pancreatic lesions: results from a prospective observational study. *Ultraschall Med* 2021; 42: 167–177
- [6] Kamata K, Takenaka M, Omoto S et al. Impact of avascular areas, as measured by contrast-enhanced harmonic EUS, on the accuracy of FNA for pancreatic adenocarcinoma. *Gastrointest Endosc* 2018; 87: 158–163 doi:10.1016/j.gie.2017.05.052
- [7] Imazu H, Uchiyama Y, Matsunaga K et al. Contrast-enhanced harmonic EUS with novel ultrasonographic contrast (Sonazoid) in the preoperative T-staging for pancreaticobiliary malignancies. *Scand J Gastroenterol* 2010; 45: 732–738
- [8] Esposito G, Massimiani G, Galasso L et al. Endoscopic contrast-enhanced ultrasound and fine-needle aspiration or biopsy for the diagnosis of pancreatic solid lesions: a systematic review and meta-analysis. *Cancers (Basel)* 2024; 16: 1658 doi:10.3390/cancers16091658
- [9] Facciorusso A, Mohan BP, Crino SF et al. Contrast-enhanced harmonic endoscopic ultrasound-guided fine-needle aspiration versus standard fine-needle aspiration in pancreatic masses: a meta-analysis. *Expert Rev Gastroenterol Hepatol* 2021; 15: 821–828 doi:10.1080/17474124.2021.1880893
- [10] Sugimoto M, Takagi T, Hikichi T et al. Conventional versus contrast-enhanced harmonic endoscopic ultrasonography-guided fine-needle aspiration for diagnosis of solid pancreatic lesions: A prospective randomized trial. *Pancreatol* 2015; 15: 538–541 doi:10.1016/j.pan.2015.06.005
- [11] Seicean A, Samarghitan A, Bolboaca SD et al. Contrast-enhanced harmonic versus standard endoscopic ultrasound-guided fine-needle aspiration in solid pancreatic lesions: a single-center prospective randomized trial. *Endoscopy* 2020; 52: 1084–1090 doi:10.1055/a-1193-4954
- [12] Cho IR, Jeong SH, Kang H et al. Comparison of contrast-enhanced versus conventional EUS-guided FNA/fine-needle biopsy in diagnosis of solid pancreatic lesions: a randomized controlled trial. *Gastrointest Endosc* 2021; 94: 303–310 doi:10.1016/j.gie.2021.01.018
- [13] Kuo YT, Chu YL, Wong WF et al. Randomized trial of contrast-enhanced harmonic guidance versus fanning technique for EUS-guided fine-needle biopsy sampling of solid pancreatic lesions. *Gastrointest Endosc* 2023; 97: 732–740 doi:10.1016/j.gie.2022.12.004
- [14] Rustagi T, Gleeson FC, Chari ST et al. Safety, diagnostic accuracy, and effects of endoscopic ultrasound fine-needle aspiration on detection of extravascular migratory metastases. *Clin Gastroenterol Hepatol* 2019; 17: 2533–2540 e1 doi:10.1016/j.cgh.2019.03.043
- [15] Ohtsuka T, Fernandez-Del Castillo C, Furukawa T et al. International evidence-based Kyoto guidelines for the management of intraductal papillary mucinous neoplasm of the pancreas. *Pancreatol* 2024; 24: 255–270
- [16] Lisotti A, Napoleon B, Facciorusso A et al. Contrast-enhanced EUS for the characterization of mural nodules within pancreatic cystic neoplasms: systematic review and meta-analysis. *Gastrointest Endosc* 2021; 94: 881–889 e5
- [17] Facciorusso A, Martina M, Buccino RV et al. Diagnostic accuracy of fine-needle aspiration of solid pancreatic lesions guided by endoscopic ultrasound elastography. *Ann Gastroenterol* 2018; 31: 513–518 doi:10.20524/aog.2018.0271
- [18] Gheorghiu M, Sparchez Z, Rusu I et al. Direct comparison of elastography endoscopic ultrasound fine-needle aspiration and B-mode endoscopic ultrasound fine-needle aspiration in diagnosing solid pancreatic lesions. *Int J Environ Res Public Health* 2022; 19: 1302 doi:10.3390/ijerph19031302
- [19] Kovacevic B, Vilmann P. EUS tissue acquisition: From A to B. *Endosc Ultrasound* 2020; 9: 225–231
- [20] Iglesias-Garcia J, Poley JW, Larghi A et al. Feasibility and yield of a new EUS histology needle: results from a multicenter, pooled, cohort study. *Gastrointest Endosc* 2011; 73: 1189–1196
- [21] Bang JY, Hawes R, Varadarajulu S. A meta-analysis comparing Pro-Core and standard fine-needle aspiration needles for endoscopic ultrasound-guided tissue acquisition. *Endoscopy* 2016; 48: 339–349 doi:10.1055/s-0034-1393354
- [22] Facciorusso A, Wani S, Triantafyllou K et al. Comparative accuracy of needle sizes and designs for EUS tissue sampling of solid pancreatic masses: a network meta-analysis. *Gastrointest Endosc* 2019; 90: 893–903 e7 doi:10.1016/j.gie.2019.07.009
- [23] Facciorusso A, Del Prete V, Buccino VR et al. Diagnostic yield of Franseen and Fork-Tip biopsy needles for endoscopic ultrasound-guided tissue acquisition: a meta-analysis. *Endosc Int Open* 2019; 7: E1221–E1230 doi:10.1055/a-0982-2997
- [24] James TW, Baron TH. A comprehensive review of endoscopic ultrasound core biopsy needles. *Expert Rev Med Devices* 2018; 15: 127–135 doi:10.1080/17434440.2018.1425137

- [25] Fabbri C, Fornelli A, Fuccio L et al. High diagnostic adequacy and accuracy of the new 20G procore needle for EUS-guided tissue acquisition: Results of a large multicentre retrospective study. *Endosc Ultrasound* 2019; 8: 261–268 doi:10.4103/eus.eus_14_19
- [26] Han S, Bhullar F, Alaber O et al. Comparative diagnostic accuracy of EUS needles in solid pancreatic masses: a network meta-analysis. *Endosc Int Open* 2021; 9: E853–E862 doi:10.1055/a-1521-0166
- [27] Gkolfakis P, Crino SF, Tziatzios G et al. Comparative diagnostic performance of end-cutting fine-needle biopsy needles for EUS tissue sampling of solid pancreatic masses: a network meta-analysis. *Gastrointest Endosc* 2022; 95: 1067–1077 e15 doi:10.1016/j.gie.2022.01.019
- [28] Ardengh JC, Brunaldi VO, Brunaldi MO et al. Is the new procore 20G double forward-bevel needle capable to obtain better histological samples by endoscopic ultrasound for diagnosing solid pancreatic lesions? *Arq Bras Cir Dig* 2021; 33: e1554 doi:10.1590/0102-672020200004e1554
- [29] Ashat M, Klair JS, Rooney SL et al. Randomized controlled trial comparing the Franseen needle with the Fork-tip needle for EUS-guided fine-needle biopsy. *Gastrointest Endosc* 2021; 93: 140–150 e2
- [30] Asokkumar R, Yung Ka C, Loh T et al. Comparison of tissue and molecular yield between fine-needle biopsy (FNB) and fine-needle aspiration (FNA): a randomized study. *Endosc Int Open* 2019; 7: E955–E963
- [31] Bang JY, Hebert-Magee S, Navaneethan U et al. EUS-guided fine needle biopsy of pancreatic masses can yield true histology. *Gut* 2018; 67: 2081–2084 doi:10.1136/gutjnl-2017-315154
- [32] Bang JY, Hebert-Magee S, Navaneethan U et al. Randomized trial comparing the Franseen and Fork-tip needles for EUS-guided fine-needle biopsy sampling of solid pancreatic mass lesions. *Gastrointest Endosc* 2018; 87: 1432–1438 doi:10.1016/j.gie.2017.11.036
- [33] Young Bang J, Krall K, Jhala N et al. Comparing needles and methods of endoscopic ultrasound-guided fine-needle biopsy to optimize specimen quality and diagnostic accuracy for patients with pancreatic masses in a randomized trial. *Clin Gastroenterol Hepatol* 2021; 19: 825–835 e7
- [34] Chen YI, Chatterjee A, Berger R et al. Endoscopic ultrasound (EUS)-guided fine needle biopsy alone vs. EUS-guided fine needle aspiration with rapid onsite evaluation in pancreatic lesions: a multicenter randomized trial. *Endoscopy* 2022; 54: 4–12
- [35] Cho E, Park CH, Kim TH et al. A prospective, randomized, multicenter clinical trial comparing 25-gauge and 20-gauge biopsy needles for endoscopic ultrasound-guided sampling of solid pancreatic lesions. *Surg Endosc* 2020; 34: 1310–1317 doi:10.1007/s00464-019-06903-x
- [36] Crino SF, Le Grazie M, Manfrin E et al. Randomized trial comparing fork-tip and side-fenestrated needles for EUS-guided fine-needle biopsy of solid pancreatic lesions. *Gastrointest Endosc* 2020; 92: 648–658 e2 doi:10.1016/j.gie.2020.05.016
- [37] Igarashi R, Irisawa A, Bhutani MS et al. The feasibility and histological diagnostic accuracy of novel Menghini needle (EUS Sonopsy CY) for endoscopic ultrasound-guided fine-needle aspiration biopsy of solid pancreatic masses: a prospective crossover study comparing standard biopsy needles. *Gastroenterol Res Pract* 2019; 2019: 5810653 doi:10.1155/2019/5810653
- [38] Kandel P, Nassar A, Gomez V et al. Comparison of endoscopic ultrasound-guided fine-needle biopsy versus fine-needle aspiration for genomic profiling and DNA yield in pancreatic cancer: a randomized crossover trial. *Endoscopy* 2021; 53: 376–382 doi:10.1055/a-1223-2171
- [39] Karsenti D, Palazzo L, Perrot B et al. 22G Acquire vs. 20G Procore needle for endoscopic ultrasound-guided biopsy of pancreatic masses: a randomized study comparing histologic sample quantity and diagnostic accuracy. *Endoscopy* 2020; 52: 747–753 doi:10.1055/a-1160-5485
- [40] Mizukawa S, Kato H, Matsumoto K et al. Effectiveness of Menghini-type needles for endoscopic ultrasound-guided fine-needle aspiration of pancreatic masses. *Dig Dis Sci* 2021; 66: 3171–3178 doi:10.1007/s10620-020-06628-1
- [41] Oh D, Kong J, Ko SW et al. A comparison between 25-gauge and 22-gauge Franseen needles for endoscopic ultrasound-guided sampling of pancreatic and peripancreatic masses: a randomized non-inferiority study. *Endoscopy* 2021; 53: 1122–1129
- [42] Oppong KW, Bekkali NLH, Leeds JS et al. Fork-tip needle biopsy versus fine-needle aspiration in endoscopic ultrasound-guided sampling of solid pancreatic masses: a randomized crossover study. *Endoscopy* 2020; 52: 454–461 doi:10.1055/a-1114-5903
- [43] Tomoda T, Kato H, Fujii Y et al. Randomized trial comparing the 25G and 22G Franseen needles in endoscopic ultrasound-guided tissue acquisition from solid pancreatic masses for adequate histological assessment. *Dig Endosc* 2022; 34: 596–603
- [44] Mendoza Ladd A, Casner N, Cherukuri SV et al. Fine needle biopsies of solid pancreatic lesions: tissue acquisition technique and needle design do not impact specimen adequacy. *Dig Dis Sci* 2022; 67: 4549–4556
- [45] Mohamadnejad M, Mirzaie V, Sotoudeh M et al. Comparing per-pass performance of 2 types of needles for EUS-guided fine-needle biopsy sampling of pancreatobiliary masses in a randomized trial. *Gastrointest Endosc* 2023; 98: 371–380 doi:10.1016/j.gie.2023.04.2070
- [46] Yousri M, Abusinna E, Tahoun N et al. A comparative study of the diagnostic utility of endoscopic ultrasound-guided fine needle aspiration cytology (EUS-FNA) versus endoscopic ultrasound-guided fine needle biopsy (EUS-FNB) in pancreatic and non-pancreatic lesions. *Asian Pac J Cancer Prev* 2022; 23: 2151–2158 doi:10.31557/APJCP.2022.23.6.2151
- [47] Barresi L, Tacelli M, Crino SF et al. Multicentric Italian survey on daily practice for autoimmune pancreatitis: Clinical data, diagnosis, treatment, and evolution toward pancreatic insufficiency. *United European Gastroenterol J* 2020; 8: 705–715 doi:10.1177/2050640620924302
- [48] Facciorusso A, Barresi L, Cannizzaro R et al. Diagnostic yield of endoscopic ultrasound-guided tissue acquisition in autoimmune pancreatitis: a systematic review and meta-analysis. *Endosc Int Open* 2021; 9: E66–E75 doi:10.1055/a-1293-7279
- [49] Jung JG, Lee JK, Lee KH et al. Comparison of endoscopic retrograde cholangiopancreatography with papillary biopsy and endoscopic ultrasound-guided pancreatic biopsy in the diagnosis of autoimmune pancreatitis. *Pancreatol* 2015; 15: 259–264
- [50] Kurita A, Yasukawa S, Zen Y et al. Comparison of a 22-gauge Franseen-tip needle with a 20-gauge forward-bevel needle for the diagnosis of type 1 autoimmune pancreatitis: a prospective, randomized, controlled, multicenter study (COMPAS study). *Gastrointest Endosc* 2020; 91: 373–381 e2
- [51] Lee SS, Dongwook O, Cho DH et al. Su1379. Comparison of 19G versus 22G reverse side-bevel needles for endoscopic ultrasound-guided pancreatic core biopsy of autoimmune pancreatitis. *Gastrointest Endosc* 2017; 85: AB357–AB358
- [52] Tsutsumi K, Ueki T, Noma Y et al. Utility of a 21-gauge Menghini-type biopsy needle with the rolling method for an endoscopic ultrasound-guided histological diagnosis of autoimmune pancreatitis: a retrospective study. *BMC Gastroenterol* 2021; 21: 21
- [53] Zator ZA, Zhu H, Cui M et al. Mo1343. Small-caliber eus-guided core biopsy needles are a safe and effective means to diagnose autoimmune pancreatitis. *Gastrointest Endosc* 2018; 87: AB454–AB455
- [54] Ishikawa T, Kawashima H, Ohno E et al. Usefulness of endoscopic ultrasound-guided fine-needle biopsy for the diagnosis of autoim-

- mune pancreatitis using a 22-gauge Franseen needle: a prospective multicenter study. *Endoscopy* 2020; 52: 978–985 doi:10.1055/a-1183-3583
- [55] Oppong KW, Maheshwari P, Nayar MK et al. Utility of endoscopic ultrasound-guided fine-needle biopsy in the diagnosis of type 1 autoimmune pancreatitis. *Endosc Int Open* 2020; 8: E1855–E1861 doi:10.1055/a-1236-3266
- [56] Noguchi K, Nakai Y, Mizuno S et al. Role of endoscopic ultrasonography-guided fine needle aspiration/biopsy in the diagnosis of autoimmune pancreatitis. *Diagnostics (Basel)* 2020; 10: 954 doi:10.3390/diagnostics10110954
- [57] Thomsen MM, Larsen MH, Di Caterino T et al. Accuracy and clinical outcomes of pancreatic EUS-guided fine-needle biopsy in a consecutive series of 852 specimens. *Endosc Ultrasound* 2022; 11: 306–318 doi:10.4103/EUS-D-21-00180
- [58] Notohara K, Kamisawa T, Kanno A et al. Efficacy and limitations of the histological diagnosis of type 1 autoimmune pancreatitis with endoscopic ultrasound-guided fine needle biopsy with large tissue amounts. *Pancreatol* 2020; 20: 834–843
- [59] Ishikawa T, Yamao K, Mizutani Y et al. A prospective study on the histological evaluation of type 1 autoimmune pancreatitis using endoscopic ultrasound-guided fine needle biopsy with a 19-gauge Franseen needle. *J Hepatobiliary Pancreat Sci* 2024; 31: 581–590
- [60] Conti Bellocchi MC, Crino SF, Bernardoni L et al. Utility of EUS-FNB with end-cutting needles in suspected focal/segmental autoimmune pancreatitis: results from a prospective study. *Endoscopy* 2023; 55: (Suppl. 02): S24–S25
- [61] Facciorusso A, Sunny SP, Del Prete V et al. Comparison between fine-needle biopsy and fine-needle aspiration for EUS-guided sampling of subepithelial lesions: a meta-analysis. *Gastrointest Endosc* 2020; 91: 14–22 e2
- [62] Facciorusso A, Crino SF, Fugazza A et al. Comparative diagnostic yield of different endoscopic techniques for tissue sampling of upper gastrointestinal subepithelial lesions: a network meta-analysis. *Endoscopy* 2024; 56: 31–40 doi:10.1055/a-2156-0063
- [63] Osoegawa T, Minoda Y, Ihara E et al. Mucosal incision-assisted biopsy versus endoscopic ultrasound-guided fine-needle aspiration with a rapid on-site evaluation for gastric subepithelial lesions: A randomized cross-over study. *Dig Endosc* 2019; 31: 413–421
- [64] Han JP, Lee TH, Hong SJ et al. EUS-guided FNA and FNB after on-site cytological evaluation in gastric subepithelial tumors. *J Dig Dis* 2016; 17: 582–587 doi:10.1111/1751-2980.12381
- [65] Sanaei O, Fernandez-Esparrach G, De La Serna-Higuera C et al. EUS-guided 22-gauge fine needle biopsy versus single-incision with needle knife for the diagnosis of upper gastrointestinal subepithelial lesions: a randomized controlled trial. *Endosc Int Open* 2020; 8: E266–E273
- [66] Zoundjiekpon V, Falt P, Fojtik P et al. Endosonography-guided fine-needle aspiration versus "key-hole biopsy" in the diagnostics of upper gastrointestinal subepithelial tumors. A prospective randomized interventional study. *Biomed Pap Med Fac Univ Palacky Olomouc Czech Repub* 2020; 164: 63–70 doi:10.5507/bp.2019.013
- [67] Wong SJ, Wang HP, Shun CT et al. Tissue diagnosis necessary for small endoscopic ultrasound-suspected gastric gastrointestinal stromal tumors 2 cm or less in size: A prospective study focusing on the endoscopic incisional biopsy. *J Gastroenterol Hepatol* 2022; 37: 1588–1595 doi:10.1111/jgh.15876
- [68] Iwai T, Kida M, Imaizumi H et al. Randomized crossover trial comparing EUS-guided fine-needle aspiration with EUS-guided fine-needle biopsy for gastric subepithelial tumors. *Diagn Cytopathol* 2018; 46: 228–233
- [69] Kim GH, Cho YK, Kim EY et al. Comparison of 22-gauge aspiration needle with 22-gauge biopsy needle in endoscopic ultrasonography-guided subepithelial tumor sampling. *Scand J Gastroenterol* 2014; 49: 347–54
- [70] Hedenstrom P, Marschall HU, Nilsson B et al. High clinical impact and diagnostic accuracy of EUS-guided biopsy sampling of subepithelial lesions: a prospective, comparative study. *Surg Endosc* 2018; 32: 1304–1313 doi:10.1007/s00464-017-5808-2
- [71] Deprez PH, Moons LMG, O'Toole D et al. Endoscopic management of subepithelial lesions including neuroendocrine neoplasms: European Society of Gastrointestinal Endoscopy (ESGE) Guideline. *Endoscopy* 2022; 54: 412–429
- [72] Facciorusso A, Crino SF, Gkolfakis P et al. Endoscopic ultrasound fine-needle biopsy vs fine-needle aspiration for lymph nodes tissue acquisition: a systematic review and meta-analysis. *Gastroenterol Rep (Oxf)* 2022; 10: goac062 doi:10.1093/gastro/goac062
- [73] Carrara S, Rahal D, Khalaf K et al. Diagnostic accuracy and safety of EUS-guided end-cutting fine-needle biopsy needles for tissue sampling of abdominal and mediastinal lymphadenopathies: a prospective multicenter series. *Gastrointest Endosc* 2023; 98: 191–198 doi:10.1016/j.gie.2023.03.018
- [74] Bang JY, Kirtane S, Krall K et al. In memoriam: Fine-needle aspiration, birth: Fine-needle biopsy: The changing trend in endoscopic ultrasound-guided tissue acquisition. *Dig Endosc* 2019; 31: 197–202 doi:10.1111/den.13280
- [75] Chin YK, Iglesias-Garcia J, de la Iglesia D et al. Accuracy of endoscopic ultrasound-guided tissue acquisition in the evaluation of lymph nodes enlargement in the absence of on-site pathologist. *World J Gastroenterol* 2017; 23: 5755–5763 doi:10.3748/wjg.v23.i31.5755
- [76] de Moura DTH, McCarty TR, Jirapinyo P et al. Endoscopic ultrasound fine-needle aspiration versus fine-needle biopsy for lymph node diagnosis: a large multicenter comparative analysis. *Clin Endosc* 2020; 53: 600–610 doi:10.5946/ce.2019.170
- [77] Hedenstrom P, Chatzikyriakos V, Shams R et al. High sensitivity of endoscopic ultrasound-guided fine-needle aspiration and endoscopic ultrasound-guided fine-needle biopsy in lymphadenopathy caused by metastatic disease: a prospective comparative study. *Clin Endosc* 2021; 54: 722–729 doi:10.5946/ce.2020.283
- [78] Hucl T, Wee E, Anuradha S et al. Feasibility and efficiency of a new 22G core needle: a prospective comparison study. *Endoscopy* 2013; 45: 792–798 doi:10.1055/s-0033-1344217
- [79] Nagula S, Pourmand K, Aslanian H et al. Comparison of endoscopic ultrasound-fine-needle aspiration and endoscopic ultrasound-fine-needle biopsy for solid lesions in a multicenter, randomized trial. *Clin Gastroenterol Hepatol* 2018; 16: 1307–1313 e1 doi:10.1016/j.cgh.2017.06.013
- [80] Sterlacci W, Sioulas AD, Veits L et al. 22-gauge core vs 22-gauge aspiration needle for endoscopic ultrasound-guided sampling of abdominal masses. *World J Gastroenterol* 2016; 22: 8820–8830 doi:10.3748/wjg.v22.i39.8820
- [81] Tanisaka Y, Mizuide M, Fujita A et al. Comparison of endoscopic ultrasound-guided fine-needle aspiration and biopsy device for lymphadenopathy. *Gastroenterol Res Pract* 2021; 2021: 6640862 doi:10.1155/2021/6640862
- [82] Facciorusso A, Crino SF, Muscatiello N et al. Endoscopic ultrasound fine-needle biopsy versus fine-needle aspiration for tissue sampling of abdominal lymph nodes: a propensity score matched multicenter comparative study. *Cancers (Basel)* 2021; 13: 4298 doi:10.3390/cancers13174298
- [83] Yang Y, ArunaCheng B et al. Comparison of fine-needle biopsy (FNB) versus fine-needle aspiration (FNA) combined with flow cytometry in the diagnosis of deep-seated lymphoma. *Diagnostics (Basel)* 2023; 13: 2777
- [84] Bang JY, Magee SH, Ramesh J et al. Randomized trial comparing fanning with standard technique for endoscopic ultrasound-guided

- fine-needle aspiration of solid pancreatic mass lesions. *Endoscopy* 2013; 45: 445–450
- [85] Lee JM, Lee HS, Hyun JJ et al. Slow-pull using a fanning technique is more useful than the standard suction technique in EUS-guided fine needle aspiration in pancreatic masses. *Gut Liver* 2018; 12: 360–366
- [86] Yang MJ, Park SW, Lee KJ et al. EUS-guided tissue acquisition using a novel torque technique is comparable with that of the fanning technique for solid pancreatic lesions: A multicenter randomized trial. *J Hepatobiliary Pancreat Sci* 2023; 30: 693–703
- [87] Park SW, Lee SS, Song TJ et al. The diagnostic performance of novel torque technique for endoscopic ultrasound-guided tissue acquisition in solid pancreatic lesions: A prospective randomized controlled trial. *J Gastroenterol Hepatol* 2020; 35: 508–515 doi:10.1111/jgh.14840
- [88] Sheng LP, Lin R, Tao X et al. Actual pressure generated by various suction technique and suctioning liquid weight through endoscopic ultrasound-guided aspiration needles. *J Dig Dis* 2022; 23: 713–719
- [89] Facciorusso A, Crino SF, Ramai D et al. Comparative diagnostic performance of different techniques for EUS-guided fine-needle biopsy sampling of solid pancreatic masses: a network meta-analysis. *Gastrointest Endosc* 2023; 97: 839–848 e5 doi:10.1016/j.gie.2023.01.024
- [90] Giri S, Afzalpurkar S, Angadi S et al. Comparison of suction techniques for EUS-guided tissue acquisition: Systematic review and network meta-analysis of randomized controlled trials. *Endosc Int Open* 2023; 11: E703–E711 doi:10.1055/a-2085-3674
- [91] Ramai D, Singh J, Kani T et al. Wet- versus dry-suction techniques for EUS-FNA of solid lesions: A systematic review and meta-analysis. *Endosc Ultrasound* 2021; 10: 319–324 doi:10.4103/EUS-D-20-00198
- [92] Nakai Y, Hamada T, Hakuta R et al. A meta-analysis of slow pull versus suction for endoscopic ultrasound-guided tissue acquisition. *Gut Liver* 2021; 15: 625–633 doi:10.5009/gnl20270
- [93] Capurso G, Archibugi L, Petrone MC et al. Slow-pull compared to suction technique for EUS-guided sampling of pancreatic solid lesions: a meta-analysis of randomized controlled trials. *Endosc Int Open* 2020; 8: E636–E643 doi:10.1055/a-1120-8428
- [94] Crino SF, Conti Bellocchi MC, Di Mitri R et al. Wet-suction versus slow-pull technique for endoscopic ultrasound-guided fine-needle biopsy: a multicenter, randomized, crossover trial. *Endoscopy* 2023; 55: 225–234
- [95] Lin MY, Wu CL, Su YY et al. Tissue quality comparison between heparinized wet suction and dry suction in endoscopic ultrasound-fine needle biopsy of solid pancreatic masses: a randomized crossover study. *Gut Liver* 2023; 17: 318–327
- [96] Zhou W, Li SY, Jiang H et al. Optimal number of needle passes during EUS-guided fine-needle biopsy of solid pancreatic lesions with 22G ProCore needles and different suction techniques: A randomized controlled trial. *Endosc Ultrasound* 2021; 10: 62–70
- [97] Costa-Moreira P, Vilas-Boas F, Martins D et al. Use of suction during endoscopic ultrasound-guided fine needle biopsy of solid pancreatic lesions with a Franseen-tip needle: a pilot comparative trial. *Endosc Int Open* 2021; 9: E401–E408
- [98] Di Mitri R, Mocciano F, Antonini F et al. Stylet slow-pull vs. standard suction technique for endoscopic ultrasound-guided fine needle biopsy in pancreatic solid lesions using 20 Gauge Procore needle: A multicenter randomized trial. *Dig Liver Dis* 2020; 52: 178–184 doi:10.1016/j.dld.2019.08.023
- [99] Tong T, Tian L, Deng M et al. Comparison between modified wet suction and dry suction technique for endoscopic ultrasound-guided fine-needle biopsy in pancreatic solid lesions. *J Gastroenterol Hepatol* 2021; 36: 1663–1669
- [100] Lee KY, Cho HD, Hwangbo Y et al. Efficacy of 3 fine-needle biopsy techniques for suspected pancreatic malignancies in the absence of an on-site cytopathologist. *Gastrointest Endosc* 2019; 89: 825–831 e1 doi:10.1016/j.gie.2018.10.042
- [101] Delgado-Cortes HM, Jaquez-Quintana JO, Gomez-Macias GS et al. Comparing fine needle biopsy techniques in solid pancreatic lesions: A prospective randomized study. *Pancreatol* 2023; 23: 836–842 doi:10.1016/j.pan.2023.09.140
- [102] Hu X, Yu F, Cao T et al. Twenty versus 40 back-and-forth needle movements for endoscopic ultrasound-guided fine-needle biopsy of solid pancreatic masses: a prospective, crossover, randomized study. *Eur J Gastroenterol Hepatol* 2023; 35: 836–842 doi:10.1097/MEG.0000000000002579
- [103] Paik WH, Choi JH, Park Y et al. Optimal techniques for EUS-guided fine-needle aspiration of pancreatic solid masses at facilities without on-site cytopathology: results from two prospective randomised trials. *J Clin Med* 2021; 10: 4662
- [104] Kataoka K, Ishikawa T, Ohno E et al. Randomized trial comparing 15 vs 5 actuations per pass during endoscopic ultrasound-guided fine-needle biopsy for specimen acquisition of solid pancreatic lesions. *J Gastroenterol Hepatol* 2023; 38: 1647–1655
- [105] Takahashi K, Yasuda I, Hayashi N et al. EUS-guided fine-needle biopsy sampling of solid pancreatic tumors with 3 versus 12 to-and-fro movements: a multicenter prospective randomized controlled study. *Gastrointest Endosc* 2023; 97: 1092–1099
- [106] Lee KH, Kim EY, Cho J et al. Risk factors associated with adverse events during endoscopic ultrasound-guided tissue sampling. *PLoS One* 2017; 12: e0189347
- [107] Facciorusso A, Bajwa HS, Menon K et al. Comparison between 22G aspiration and 22G biopsy needles for EUS-guided sampling of pancreatic lesions: A meta-analysis. *Endosc Ultrasound* 2020; 9: 167–174
- [108] van Riet PA, Erler NS, Bruno MJ et al. Comparison of fine-needle aspiration and fine-needle biopsy devices for endoscopic ultrasound-guided sampling of solid lesions: a systemic review and meta-analysis. *Endoscopy* 2021; 53: 411–423 doi:10.1055/a-1206-5552
- [109] Li Z, Liu W, Xu X et al. A meta-analysis comparing endoscopic ultrasound-guided fine-needle aspiration with endoscopic ultrasound-guided fine-needle biopsy. *J Clin Gastroenterol* 2022; 56: 668–678
- [110] Yao DW, Qin MZ, Jiang HX et al. Comparison of EUS-FNA and EUS-FNB for diagnosis of solid pancreatic mass lesions: a meta-analysis of prospective studies. *Scand J Gastroenterol* 2024; 59: 1–8
- [111] Hassan GM, Laporte L, Paquin SC et al. Endoscopic ultrasound guided fine needle aspiration versus endoscopic ultrasound guided fine needle biopsy for pancreatic cancer diagnosis: a systematic review and meta-analysis. *Diagnostics (Basel)* 2022; 12: 2951 doi:10.3390/diagnostics12122951
- [112] Bang JY, Hebert-Magee S, Trevino J et al. Randomized trial comparing the 22-gauge aspiration and 22-gauge biopsy needles for EUS-guided sampling of solid pancreatic mass lesions. *Gastrointest Endosc* 2012; 76: 321–327 doi:10.1016/j.gie.2012.03.1392
- [113] Iwashita T, Nakai Y, Samarasena JB et al. High single-pass diagnostic yield of a new 25-gauge core biopsy needle for EUS-guided FNA biopsy in solid pancreatic lesions. *Gastrointest Endosc* 2013; 77: 909–915 doi:10.1016/j.gie.2013.01.001
- [114] Lee YN, Moon JH, Kim HK et al. Core biopsy needle versus standard aspiration needle for endoscopic ultrasound-guided sampling of solid pancreatic masses: a randomized parallel-group study. *Endoscopy* 2014; 46: 1056–1062 doi:10.1055/s-0034-1377558
- [115] Mohamadnejad M, Mullady D, Early DS et al. Increasing number of passes beyond 4 does not increase sensitivity of detection of pancreatic malignancy by endoscopic ultrasound-guided fine-needle aspiration. *Clin Gastroenterol Hepatol* 2017; 15: 1071–1078 e2
- [116] Ge PS, Wani S, Watson RR et al. Per-pass performance characteristics of endoscopic ultrasound-guided fine-needle aspiration of malign-

- nant solid pancreatic masses in a large multicenter cohort. *Pancreas* 2018; 47: 296–301 doi:10.1097/MPA.0000000000001003
- [117] Mita N, Iwashita T, Uemura S et al. Endoscopic ultrasound-guided fine needle biopsy using 22-gauge Franseen needle for the histological diagnosis of solid lesions: a multicenter prospective pilot study. *Dig Dis Sci* 2020; 65: 1155–1163 doi:10.1007/s10620-019-05840-y
- [118] Inoue T, Tsuzuki T, Takahara T et al. Prospective evaluation of 25-gauge Franseen needles for endoscopic ultrasound-guided fine-needle biopsy of solid pancreatic masses. *Endosc Int Open* 2020; 8: E566–E570 doi:10.1055/a-1119-6673
- [119] Teodorescu C, Gheorghiu M, Zaharie T et al. Endoscopic ultrasonography-fine needle aspiration of solid pancreatic masses: Do we need the fourth pass? A prospective study *Diagn Cytopathol* 2021; 49: 395–403 doi:10.1002/dc.24669
- [120] Suzuki M, Sekino Y, Hosono K et al. Optimal number of needle punctures in endoscopic ultrasound-guided fine-needle biopsy for gastric subepithelial lesions without rapid on-site evaluation. *J Med Ultrason (2001)* 2021; 48: 623–629
- [121] Itonaga M, Yasukawa S, Fukutake N et al. Comparison of 22-gauge standard and Franseen needles in EUS-guided tissue acquisition for diagnosing solid pancreatic lesions: a multicenter randomized controlled trial. *Gastrointest Endosc* 2022; 96: 57–66 e2 doi:10.1016/j.gie.2022.02.005
- [122] Mangiavillano B, Facciorusso A, di Matteo FM et al. Establishing the optimal number of passes during EUS-FNB for diagnosis of pancreatic solid lesions: Prospective multicenter study. *Endosc Int Open* 2024; 12: E467–E473
- [123] Mangiavillano B, Crino SF, Facciorusso A et al. Endoscopic ultrasound-guided fine-needle biopsy with or without macroscopic on-site evaluation: a randomized controlled noninferiority trial. *Endoscopy* 2023; 55: 129–137 doi:10.1055/a-1915-5263
- [124] Chalhoub JM, Hawa F, Grantham T et al. Effect of the number of passes on diagnostic performance of EUS-fine needle biopsy of solid pancreatic masses: A systematic review and meta-analysis. *Gastrointest Endosc* 2024; 100: 595–604. e8
- [125] Bang JY, Jhala N, Seth A et al. Standardisation of EUS-guided FNB technique for molecular profiling in pancreatic cancer: results of a randomised trial. *Gut* 2023; 72: 1255–1257 doi:10.1136/gutjnl-2023-329495
- [126] Aslanian HR, Estrada JD, Rossi F et al. Endoscopic ultrasound and endoscopic retrograde cholangiopancreatography for obstructing pancreas head masses: combined or separate procedures? *J Clin Gastroenterol* 2011; 45: 711–713 doi:10.1097/MCG.0b013e3182045923
- [127] Siddiqui AA, Fein M, Kowalski TE et al. Comparison of the influence of plastic and fully covered metal biliary stents on the accuracy of EUS-FNA for the diagnosis of pancreatic cancer. *Dig Dis Sci* 2012; 57: 2438–2445 doi:10.1007/s10620-012-2170-z
- [128] Bekkali NLH, Nayar MK, Leeds JS et al. Impact of metal and plastic stents on endoscopic ultrasound-guided aspiration cytology and core histology of head of pancreas masses. *Endoscopy* 2019; 51: 1044–1050 doi:10.1055/a-0824-6982
- [129] Crino SF, Conti Bellocchi MC, Antonini F et al. Impact of biliary stents on the diagnostic accuracy of EUS-guided fine-needle biopsy of solid pancreatic head lesions: A multicenter study. *Endosc Ultrasound* 2021; 10: 440–447
- [130] Ranney N, Phadnis M, Trevino J et al. Impact of biliary stents on EUS-guided FNA of pancreatic mass lesions. *Gastrointest Endosc* 2012; 76: 76–83 doi:10.1016/j.gie.2012.02.049
- [131] Kim JJ, Walia S, Lee SH et al. Lower yield of endoscopic ultrasound-guided fine-needle aspiration in patients with pancreatic head mass with a biliary stent. *Dig Dis Sci* 2015; 60: 543–549
- [132] Antonini F, Fuccio L, Giorgini S et al. Biliary plastic stent does not influence the accuracy of endoscopic ultrasound-guided sampling of pancreatic head masses performed with core biopsy needles. *Dig Liver Dis* 2017; 49: 898–902
- [133] Fisher JM, Gordon SR, Gardner TB. The impact of prior biliary stenting on the accuracy and complication rate of endoscopic ultrasound fine-needle aspiration for diagnosing pancreatic adenocarcinoma. *Pancreas* 2011; 40: 21–24 doi:10.1097/MPA.0b013e3181f66e64
- [134] Constantinescu A, Plotogea OM, Stan-Ilie M et al. Impact of biliary stenting in endoscopic ultrasound-guided tissue acquisition among patients with pancreatic cancer. *J Clin Ultrasound* 2022; 50: 844–849
- [135] Facciorusso A, Chandan S, Gkolfakis P et al. Do biliary stents affect EUS-guided tissue acquisition (EUS-TA) in solid pancreatic lesions determining biliary obstruction? a literature review with meta-analysis *Cancers (Basel)* 2023; 15: 1789
- [136] Wyse J, Rubino M, Iglesias Garcia J et al. Onsite evaluation of endoscopic ultrasound fine needle aspiration: the endosonographer, the cytotechnologist and the cytopathologist. *Rev Esp Enferm Dig* 2017; 109: 279–283
- [137] Savoy AD, Raimondo M, Woodward TA et al. Can endosonographers evaluate on-site cytologic adequacy? A comparison with cytotechnologists *Gastrointest Endosc* 2007; 65: 953–957
- [138] Nebel JA, Soldan M, Dumonceau JM et al. Rapid on-site evaluation by endosonographer of endoscopic ultrasound fine-needle aspiration of solid pancreatic lesions: a randomized controlled trial. *Pancreas* 2021; 50: 815–821 doi:10.1097/MPA.0000000000001846
- [139] Zhang S, Ni M, Wang P et al. Diagnostic value of endoscopic ultrasound-guided fine needle aspiration with rapid on-site evaluation performed by endoscopists in solid pancreatic lesions: A prospective, randomized controlled trial. *J Gastroenterol Hepatol* 2022; 37: 1975–1982
- [140] Eloubeidi MA, Tamhane A, Jhala N et al. Agreement between rapid onsite and final cytologic interpretations of EUS-guided FNA specimens: implications for the endosonographer and patient management. *Am J Gastroenterol* 2006; 101: 2841–2847
- [141] Lin R, Sheng LP, Han CQ et al. Application of artificial intelligence to digital-rapid on-site cytopathology evaluation during endoscopic ultrasound-guided fine needle aspiration: A proof-of-concept study. *J Gastroenterol Hepatol* 2023; 38: 883–887
- [142] Wani S MV, Komanduri S, Watson RR et al. 1040. Fine needle biopsy (FNB) is more cost-effective than fine needle aspiration (FNA) for endoscopic ultrasound guided tissue sampling: an economic analysis. *Gastrointest Endosc* 2014; 79: AB189
- [143] Khoury T, Sbeit W. Cost-effectiveness of rapid on-site evaluation of endoscopic ultrasound fine needle aspiration in gastrointestinal lesions. *Cytopathology* 2021; 32: 326–330 doi:10.1111/cyt.12962
- [144] Sbeit W, Khoury T. Endoscopic ultrasound fine needle biopsy was not more cost-effective than fine-needle aspiration with rapid on-site evaluation in gastrointestinal lesions diagnosis. *Diagn Cytopathol* 2021; 49: 944–947 doi:10.1111/cyt.12962
- [145] Matynia AP, Schmidt RL, Barraza G et al. Impact of rapid on-site evaluation on the adequacy of endoscopic-ultrasound guided fine-needle aspiration of solid pancreatic lesions: a systematic review and meta-analysis. *J Gastroenterol Hepatol* 2014; 29: 697–705 doi:10.1111/jgh.12431
- [146] Hebert-Magee S, Bae S, Varadarajulu S et al. The presence of a cytopathologist increases the diagnostic accuracy of endoscopic ultrasound-guided fine needle aspiration cytology for pancreatic adenocarcinoma: a meta-analysis. *Cytopathology* 2013; 24: 159–171 doi:10.1111/cyt.12071
- [147] Kappelle WFW, van Leerdam ME, Schwartz MP et al. Rapid on-site evaluation during endoscopic ultrasound-guided fine-needle aspiration of lymph nodes does not increase diagnostic yield: A randomized, multicenter trial. *Am J Gastroenterol* 2018; 113: 677–685

- [148] van Riet PA, Cahen DL, Poley JW et al. Mapping international practice patterns in EUS-guided tissue sampling: outcome of a global survey. *Endosc Int Open* 2016; 4: E360–E370 doi:10.1055/s-0042-101023
- [149] Crino SF, Di Mitri R, Nguyen NQ et al. Endoscopic ultrasound-guided fine-needle biopsy with or without rapid on-site evaluation for diagnosis of solid pancreatic lesions: a randomized controlled non-inferiority trial. *Gastroenterology* 2021; 161: 899–909 e5 doi:10.1053/j.gastro.2021.06.005
- [150] Facciorusso A, Gkolfakis P, Tziatzios G et al. Comparison between EUS-guided fine-needle biopsy with or without rapid on-site evaluation for tissue sampling of solid pancreatic lesions: A systematic review and meta-analysis. *Endosc Ultrasound* 2022; 11: 458–465 doi:10.4103/EUS-D-22-00026
- [151] Khurana AK, Graber B, Wang D et al. Telecytopathology for on-site adequacy evaluation decreases the nondiagnostic rate in endoscopic ultrasound-guided fine-needle aspiration of pancreatic lesions. *Telemed J E Health* 2014; 20: 822–827 doi:10.1089/tmj.2013.0316
- [152] Machado RS, Richa R, Callegari F et al. Instant messenger smart-phone application for endosonographer/cytopathologist real-time interaction at a distance in EUS-FNA for solid pancreatic lesions. *Endosc Int Open* 2019; 7: E1027–E1030 doi:10.1055/a-0965-6631
- [153] de Moura DTH, McCarty TR, Jirapinyo P et al. Evaluation of endoscopic ultrasound fine-needle aspiration versus fine-needle biopsy and impact of rapid on-site evaluation for pancreatic masses. *Endosc Int Open* 2020; 8: E738–E747 doi:10.1055/a-1122-8674
- [154] Fitzpatrick MJ, Hernandez-Barco YG, Krishnan K et al. Evaluating triage protocols for endoscopic ultrasound-guided fine needle biopsies of the pancreas. *J Am Soc Cytopathol* 2020; 9: 396–404 doi:10.1016/j.jasc.2020.05.008
- [155] Fabbri C, Fuccio L, Fornelli A et al. The presence of rapid on-site evaluation did not increase the adequacy and diagnostic accuracy of endoscopic ultrasound-guided tissue acquisition of solid pancreatic lesions with core needle. *Surg Endosc* 2017; 31: 225–230
- [156] Gines A, Fusaroli P, Sendino O et al. Performance of a new flexible 19 G EUS needle in pancreatic solid lesions located in the head and uncinate process: A prospective multicenter study. *Endosc Int Open* 2021; 9: E1269–E1275 doi:10.1055/a-1480-0428
- [157] Soto-Solis R, Paz MP, Torres-Ruiz MI et al. Rapid on-site cytologic evaluation during endoscopic ultrasound-guided biopsies of pancreatic solid lesions. *Cir Cir* 2020; 88: 435–440
- [158] Mahmood SK, Abdelfattah A, Joyce AM et al. SU1356. Sharkcore pancreatic biopsies with rose (rapid on-site evaluation) have a higher diagnostic yield than Sharkcore biopsies without rose. *Gastrointest Endosc* 2017; 86: AB348–AB349
- [159] Iwashita T, Yasuda I, Mukai T et al. Macroscopic on-site quality evaluation of biopsy specimens to improve the diagnostic accuracy during EUS-guided FNA using a 19-gauge needle for solid lesions: a single-center prospective pilot study (MOSE study). *Gastrointest Endosc* 2015; 81: 177–185
- [160] Chong CCN, Lakhtakia S, Nguyen N et al. Endoscopic ultrasound-guided tissue acquisition with or without macroscopic on-site evaluation: randomized controlled trial. *Endoscopy* 2020; 52: 856–863 doi:10.1055/a-1172-6027
- [161] Sundaram S, Chhanchure U, Patil P et al. Rapid on-site evaluation (ROSE) versus macroscopic on-site evaluation (MOSE) for endoscopic ultrasound-guided sampling of solid pancreatic lesions: a paired comparative analysis using newer-generation fine needle biopsy needles. *Ann Gastroenterol* 2023; 36: 340–346 doi:10.20524/aog.2023.0790
- [162] Stigliano S, Balassone V, Biasutto D et al. Accuracy of visual on-site evaluation (Vose) In predicting the adequacy of Eus-guided fine needle biopsy: A single center prospective study. *Pancreatology* 2021; 21: 312–317 doi:10.1016/j.pan.2020.12.011
- [163] Mohan BP, Madhu D, Reddy N et al. Diagnostic accuracy of EUS-guided fine-needle biopsy sampling by macroscopic on-site evaluation: a systematic review and meta-analysis. *Gastrointest Endosc* 2022; 96: 909–917 e11 doi:10.1016/j.gie.2022.07.026
- [164] Stigliano S, Crescenzi A, Taffon C et al. Role of fluorescence confocal microscopy for rapid evaluation of EUS fine-needle biopsy sampling in pancreatic solid lesions. *Gastrointest Endosc* 2021; 94: 562–568 e1 doi:10.1016/j.gie.2021.03.029
- [165] Amendoeira I, Arcidiacono PG, Barizzi J et al. New digital confocal laser microscopy may boost real-time evaluation of endoscopic ultrasound-guided fine-needle biopsy (EUS-FNB) from solid pancreatic lesions: Data from an international multicenter study. *EBioMedicine* 2022; 86: 104377
- [166] Salvia R, Burelli A, Nepi A et al. Pancreatic cystic neoplasms: Still high rates of preoperative misdiagnosis in the guidelines and endoscopic ultrasound era. *Surgery* 2023; 174: 1410–1415 doi:10.1016/j.surg.2023.07.016
- [167] Zhu H, Jiang F, Zhu J et al. Assessment of morbidity and mortality associated with endoscopic ultrasound-guided fine-needle aspiration for pancreatic cystic lesions: A systematic review and meta-analysis. *Dig Endosc* 2017; 29: 667–675
- [168] Leung KK, Ross WA, Evans D et al. Pancreatic cystic neoplasm: the role of cyst morphology, cyst fluid analysis, and expectant management. *Ann Surg Oncol* 2009; 16: 2818–2824 doi:10.1245/s10434-009-0502-9
- [169] Bick BL, Enders FT, Levy MJ et al. The string sign for diagnosis of mucinous pancreatic cysts. *Endoscopy* 2015; 47: 626–631 doi:10.1055/s-0034-1391484
- [170] Brugge WR, Lewandrowski K, Lee-Lewandrowski E et al. Diagnosis of pancreatic cystic neoplasms: a report of the cooperative pancreatic cyst study. *Gastroenterology* 2004; 126: 1330–1336 doi:10.1053/j.gastro.2004.02.013
- [171] Kwan MC, Pitman MB, Fernandez-Del Castillo C et al. Revisiting the performance of cyst fluid carcinoembryonic antigen as a diagnostic marker for pancreatic mucinous cysts: a comprehensive 20-year institutional review. *Gut* 2024; 73: 629–638
- [172] Oppong KW, Dawwas MF, Charnley RM et al. EUS and EUS-FNA diagnosis of suspected pancreatic cystic neoplasms: Is the sum of the parts greater than the CEA? *Pancreatology* 2015; 15: 531–537
- [173] van der Waaij LA, van Dullemen HM, Porte RJ. Cyst fluid analysis in the differential diagnosis of pancreatic cystic lesions: a pooled analysis. *Gastrointest Endosc* 2005; 62: 383–389 doi:10.1016/s0016-5107(05)01581-6
- [174] Zikos T, Pham K, Bowen R et al. Cyst fluid glucose is rapidly feasible and accurate in diagnosing mucinous pancreatic cysts. *Am J Gastroenterol* 2015; 110: 909–914 doi:10.1038/ajg.2015.148
- [175] Mohan BP, Madhu D, Khan SR et al. Intracystic glucose levels in differentiating mucinous from nonmucinous pancreatic cysts: a systematic review and meta-analysis. *J Clin Gastroenterol* 2022; 56: e131–e136
- [176] Gorris M, Dijk F, Farina A et al. Validation of combined carcinoembryonic antigen and glucose testing in pancreatic cyst fluid to differentiate mucinous from non-mucinous cysts. *Surg Endosc* 2023; 37: 3739–3746
- [177] McCarty TR, Garg R, Rustagi T. Pancreatic cyst fluid glucose in differentiating mucinous from nonmucinous pancreatic cysts: a systematic review and meta-analysis. *Gastrointest Endosc* 2021; 94: 698–712 e6 doi:10.1016/j.gie.2021.04.025
- [178] Rossi G, Petrone MC, Tacelli M et al. Glucose and lactate levels are lower in EUS-aspirated cyst fluid of mucinous vs non-mucinous pancreatic cystic lesions. *Dig Liver Dis* 2024; 56: 836–840 doi:10.1016/j.dld.2023.11.013
- [179] Thosani N, Thosani S, Qiao W et al. Role of EUS-FNA-based cytology in the diagnosis of mucinous pancreatic cystic lesions: a systematic

- review and meta-analysis. *Dig Dis Sci* 2010; 55: 2756–66 doi:10.1007/s10620-010-1361-8
- [180] Nikiforova MN, Khalid A, Fasanella KE et al. Integration of KRAS testing in the diagnosis of pancreatic cystic lesions: a clinical experience of 618 pancreatic cysts. *Mod Pathol* 2013; 26: 1478–1487 doi:10.1038/modpathol.2013.91
- [181] Pan S, Brand RE, Lai LA et al. Proteome heterogeneity and malignancy detection in pancreatic cyst fluids. *Clin Transl Med* 2021; 11: e506 doi:10.1002/ctm2.506
- [182] Pfluger MJ, Jamouss KT, Afghani E et al. Predictive ability of pancreatic cyst fluid biomarkers: A systematic review and meta-analysis. *Pancreatology* 2023; 23: 868–877 doi:10.1016/j.pan.2023.05.005
- [183] Khan I, Baig M, Bandepalle T et al. Utility of cyst fluid carcinoembryonic antigen in differentiating mucinous and non-mucinous pancreatic cysts: an updated meta-analysis. *Dig Dis Sci* 2022; 67: 4541–4548 doi:10.1007/s10620-021-07315-5
- [184] Guzman-Calderon E, Md BM, Casellas JA et al. Intracystic glucose levels appear useful for diagnosis of pancreatic cystic lesions: a systematic review and meta-analysis. *Dig Dis Sci* 2022; 67: 2562–2570 doi:10.1007/s10620-021-07035-w
- [185] Faias S, Cravo M, Chaves P et al. Comparative analysis of glucose and carcinoembryonic antigen in the diagnosis of pancreatic mucinous cysts: a systematic review and meta-analysis. *Gastrointest Endosc* 2021; 94: 235–247 doi:10.1016/j.gie.2021.03.935
- [186] McCarty TR, Paleti S, Rustagi T. Molecular analysis of EUS-acquired pancreatic cyst fluid for KRAS and GNAS mutations for diagnosis of intraductal papillary mucinous neoplasia and mucinous cystic lesions: a systematic review and meta-analysis. *Gastrointest Endosc* 2021; 93: 1019–1033 e5 doi:10.1016/j.gie.2020.12.014
- [187] Crino SF, Bernardoni L, Gabbriellini A et al. Beyond pancreatic cyst epithelium: evidence of ovarian-like stroma in EUS-guided through-the-needle micro-forceps biopsy specimens. *Am J Gastroenterol* 2018; 113: 1059–1060 doi:10.1038/s41395-018-0124-6
- [188] Kovacevic B, Klausen P, Rift CV et al. Clinical impact of endoscopic ultrasound-guided through-the-needle microbiopsy in patients with pancreatic cysts. *Endoscopy* 2021; 53: 44–52
- [189] Astbury S, Baskar A, Grove JI et al. Next-generation sequencing of pancreatic cyst wall specimens obtained using micro-forceps for improving diagnostic accuracy. *Endosc Int Open* 2023; 11: E983–E991
- [190] Rift CV, Melchior LC, Kovacevic B et al. Targeted next-generation sequencing of EUS-guided through-the-needle-biopsy sampling from pancreatic cystic lesions. *Gastrointest Endosc* 2023; 97: 50–58 e4
- [191] Yang D, Trindade AJ, Yachimski P et al. Histologic analysis of endoscopic ultrasound-guided through the needle microforceps biopsies accurately identifies mucinous pancreas cysts. *Clin Gastroenterol Hepatol* 2019; 17: 1587–1596
- [192] Larghi A, Manfrin E, Fabbri C et al. Interobserver agreement among expert pathologists on through-the-needle microforceps biopsy samples for evaluation of pancreatic cystic lesions. *Gastrointest Endosc* 2019; 90: 784–792 e4
- [193] Facciorusso A, Ramai D, Gkolfakis P et al. Through-the-needle biopsy of pancreatic cystic lesions: current evidence and implications for clinical practice. *Expert Rev Med Devices* 2021; 18: 1165–1174 doi:10.1080/17434440.2021.2012450
- [194] Kovacevic B, Kalaitzakis E, Klausen P et al. EUS-guided through-the-needle microbiopsy of pancreatic cysts: Technical aspects (with video). *Endosc Ultrasound* 2020; 9: 220–224
- [195] Crino SF, Bernardoni L, Brozzi L et al. Association between macroscopically visible tissue samples and diagnostic accuracy of EUS-guided through-the-needle microforceps biopsy sampling of pancreatic cystic lesions. *Gastrointest Endosc* 2019; 90: 933–943
- [196] Crino SF, Ammendola S, Gabbriellini A et al. Time to standardize through-the-needle biopsy specimen handling. *Gastrointest Endosc* 2020; 92: 981–983 doi:10.1016/j.gie.2020.05.009
- [197] Tacelli M, Bina N, Crino SF et al. Reliability of grading preoperative pancreatic neuroendocrine tumors on EUS specimens: a systematic review with meta-analysis of aggregate and individual data. *Gastrointest Endosc* 2022; 96: 898–908 e23
- [198] Melita G, Pallio S, Tortora A et al. Diagnostic and interventional role of endoscopic ultrasonography for the management of pancreatic neuroendocrine neoplasms. *J Clin Med* 2021; 10: 2638 doi:10.3390/jcm10122638
- [199] Conti Bellocchi MC, Manfrin E, Brillo A et al. Rare pancreatic/peri-pancreatic cystic lesions can be accurately characterized by EUS with through-the-needle biopsy - a unique pictorial essay with clinical and histopathological correlations. *Diagnostics (Basel)* 2023; 13: 3663
- [200] Crino SF, Bernardoni L, Manfrin E et al. Endoscopic ultrasound features of pancreatic schwannoma. *Endosc Ultrasound* 2016; 5: 396–398 doi:10.4103/2303-9027.195873
- [201] Crino SF. Through-the-needle microforceps biopsy: a powerful tool but for selected patients. *Endoscopy* 2021; 53: 53–54 doi:10.1055/a-1243-0545
- [202] McCarty T, Rustagi T. Endoscopic ultrasound-guided through-the-needle microforceps biopsy improves diagnostic yield for pancreatic cystic lesions: a systematic review and meta-analysis. *Endosc Int Open* 2020; 8: E1280–E1290 doi:10.1055/a-1194-4085
- [203] Facciorusso A, Del Prete V, Antonino M et al. Diagnostic yield of EUS-guided through-the-needle biopsy in pancreatic cysts: a meta-analysis. *Gastrointest Endosc* 2020; 92: 1–8 e3 doi:10.1016/j.gie.2020.01.038
- [204] Tacelli M, Celsa C, Magro B et al. Diagnostic performance of endoscopic ultrasound through-the-needle microforceps biopsy of pancreatic cystic lesions: Systematic review with meta-analysis. *Dig Endosc* 2020; 32: 1018–1030
- [205] Westerveld DR, Ponniah SA, Draganov PV et al. Diagnostic yield of EUS-guided through-the-needle microforceps biopsy versus EUS-FNA of pancreatic cystic lesions: a systematic review and meta-analysis. *Endosc Int Open* 2020; 8: E656–E667 doi:10.1055/a-1119-6543
- [206] Kovacevic B, Antonelli G, Klausen P et al. EUS-guided biopsy versus confocal laser endomicroscopy in patients with pancreatic cystic lesions: A systematic review and meta-analysis. *Endosc Ultrasound* 2021; 10: 270–279
- [207] Gopakumar H, Puli SR. Value of Endoscopic ultrasound-guided through-the-needle biopsy in pancreatic cystic lesions. a systematic review and meta-analysis. *J Gastrointest Cancer* 2024; 55: 15–25 doi:10.1007/s12029-023-00949-w
- [208] Facciorusso A, Arevalo-Mora M, Conti Bellocchi MC et al. Impact of antibiotic prophylaxis on infection rate after endoscopic ultrasound through-the-needle biopsy of pancreatic cysts: a propensity score-matched study. *Diagnostics (Basel)* 2022; 12: 211
- [209] Facciorusso A, Kovacevic B, Yang D et al. Predictors of adverse events after endoscopic ultrasound-guided through-the-needle biopsy of pancreatic cysts: a recursive partitioning analysis. *Endoscopy* 2022; 54: 1158–1168 doi:10.1055/a-1831-5385
- [210] Rift CV, Scheie D, Toxvaerd A et al. Diagnostic accuracy of EUS-guided through-the-needle-biopsies and simultaneously obtained fine needle aspiration for cytology from pancreatic cysts: A systematic review and meta-analysis. *Pathol Res Pract* 2021; 220: 153368
- [211] Li SY, Wang ZJ, Pan CY et al. Comparative performance of endoscopic ultrasound-based techniques in patients with pancreatic cystic lesions: a network meta-analysis. *Am J Gastroenterol* 2023; 118: 243–255

- [212] Napoleon B, Krishna SG, Marco B et al. Confocal endomicroscopy for evaluation of pancreatic cystic lesions: a systematic review and international Delphi consensus report. *Endosc Int Open* 2020; 8: E1566–E1581 doi:10.1055/a-1229-4156
- [213] Karia K, Waxman I, Konda VJ et al. Needle-based confocal endomicroscopy for pancreatic cysts: the current agreement in interpretation. *Gastrointest Endosc* 2016; 83: 924–927 doi:10.1016/j.gie.2015.08.080
- [214] Napoleon B, Lemaistre AI, Pujol B et al. In vivo characterization of pancreatic cystic lesions by needle-based confocal laser endomicroscopy (nCLE): proposition of a comprehensive nCLE classification confirmed by an external retrospective evaluation. *Surg Endosc* 2016; 30: 2603–2612 doi:10.1007/s00464-015-4510-5
- [215] Krishna SG, Brugge WR, Dewitt JM et al. Needle-based confocal laser endomicroscopy for the diagnosis of pancreatic cystic lesions: an international external interobserver and intraobserver study (with videos). *Gastrointest Endosc* 2017; 86: 644–654 e2
- [216] Krishna SG, Lee JH. Appraisal of needle-based confocal laser endomicroscopy in the diagnosis of pancreatic cysts. *World J Gastroenterol* 2016; 22: 1701–1710 doi:10.3748/wjg.v22.i4.1701
- [217] Nakai Y, Iwashita T, Park DH et al. Diagnosis of pancreatic cysts: EUS-guided, through-the-needle confocal laser-induced endomicroscopy and cystoscopy trial: DETECT study. *Gastrointest Endosc* 2015; 81: 1204–1214 doi:10.1016/j.gie.2014.10.025
- [218] Le Pen C, Palazzo L, Napoleon B. A health economic evaluation of needle-based confocal laser endomicroscopy for the diagnosis of pancreatic cysts. *Endosc Int Open* 2017; 5: E987–E995 doi:10.1055/s-0043-117947
- [219] Facciorusso A, Buccino VR, Sacco R. Needle-based confocal laser endomicroscopy in pancreatic cysts: a meta-analysis. *Eur J Gastroenterol Hepatol* 2020; 32: 1084–1090 doi:10.1097/MEG.0000000000001728
- [220] Konjeti VR, McCarty TR, Rustagi T. Needle-based confocal laser endomicroscopy (nCLE) for evaluation of pancreatic cystic lesions: a systematic review and meta-analysis. *J Clin Gastroenterol* 2022; 56: 72–80 doi:10.1097/MCG.0000000000001468
- [221] Saghir SM, Dhindsa BS, Daid SGS et al. Efficacy of EUS-guided needle-based confocal laser endomicroscopy in the diagnosis of pancreatic lesions: A systematic review and meta-analysis. *Endosc Ultrasound* 2022; 11: 275–282 doi:10.4103/EUS-D-20-00122
- [222] Wang X, Hu J, Yang F et al. Needle-based confocal laser endomicroscopy for diagnosis of pancreatic cystic lesions: a meta-analysis. *Minim Invasive Ther Allied Technol* 2022; 31: 653–663 doi:10.1080/13645706.2021.1888750
- [223] ASGE Standards of Practice Committee. Khashab MA, Chithadi KV et al. Antibiotic prophylaxis for GI endoscopy. *Gastrointest Endosc* 2015; 81: 81–89
- [224] Colan-Hernandez J, Sendino O, Loras C et al. Antibiotic prophylaxis is not required for endoscopic ultrasonography-guided fine-needle aspiration of pancreatic cystic lesions, based on a randomized trial. *Gastroenterology* 2020; 158: 1642–1649 e1 doi:10.1053/j.gastro.2020.01.025
- [225] Facciorusso A, Mohan BP, Tacelli M et al. Use of antibiotic prophylaxis is not needed for endoscopic ultrasound-guided fine-needle aspiration of pancreatic cysts: a meta-analysis. *Expert Rev Gastroenterol Hepatol* 2020; 14: 999–1005 doi:10.1080/17474124.2020.1797486
- [226] Palomera-Tejeda E, Shah H, Attar BM et al. Prophylactic antibiotics do not prevent infectious complications of endoscopic ultrasound fine-needle aspiration of pancreatic cysts: a systematic review and meta-analysis. *Pancreas* 2021; 50: 667–672 doi:10.1097/MPA.0000000000001816
- [227] Guarner-Argente C, Shah P, Buchner A et al. Use of antimicrobials for EUS-guided FNA of pancreatic cysts: a retrospective, comparative analysis. *Gastrointest Endosc* 2011; 74: 81–86 doi:10.1016/j.gie.2011.03.1244
- [228] Facciorusso A, Buccino VR, Turco A et al. Antibiotics do not decrease the rate of infection after endoscopic ultrasound fine-needle aspiration of pancreatic cysts. *Dig Dis Sci* 2019; 64: 2308–2315 doi:10.1007/s10620-019-05655-x
- [229] Badrinath M, Kanagalingam G, Iorio N et al. 113. Are antibiotics necessary for EUS-FNA of pancreatic cysts: a retrospective study. *Am J Gastroenterol* 2019; 114: S69
- [230] Lee LS, Saltzman JR, Bounds BC et al. EUS-guided fine needle aspiration of pancreatic cysts: a retrospective analysis of complications and their predictors. *Clin Gastroenterol Hepatol* 2005; 3: 231–236
- [231] Torous VF, Cuda JM, Manucha V et al. Cell blocks in cytology: review of preparation methods, advantages, and limitations. *J Am Soc Cytopathol* 2023; 12: 77–88 doi:10.1016/j.jasc.2022.11.003
- [232] Takahashi K, Yasuda I, Hanaoka T et al. Comparison of histological sample volumes among various endoscopic ultrasound-guided biopsy needles. *J Clin Med* 2021; 10: 3560
- [233] Crino SF, Larghi A, Bernardoni L et al. Touch imprint cytology on endoscopic ultrasound fine-needle biopsy provides comparable sample quality and diagnostic yield to standard endoscopic ultrasound fine-needle aspiration specimens in the evaluation of solid pancreatic lesions. *Cytopathology* 2019; 30: 179–186 doi:10.1111/cyt.12662
- [234] Yoon WJ, Bishop Pitman M. Cytology specimen management, triage and standardized reporting of fine needle aspiration biopsies of the pancreas. *J Pathol Transl Med* 2015; 49: 364–372 doi:10.4132/jptm.2015.07.19
- [235] Wong N. My approach to endoscopic ultrasound-guided fine-needle aspiration biopsy specimens of the pancreas. *J Clin Pathol* 2020; 73: 297–309 doi:10.1136/jclinpath-2019-206331
- [236] Ieni A, Todaro P, Crino SF et al. Endoscopic ultrasound-guided fine-needle aspiration cytology in pancreaticobiliary carcinomas: diagnostic efficacy of cell-block immunocytochemistry. *Hepatobiliary Pancreat Dis Int* 2015; 14: 305–312 doi:10.1016/s1499-3872(15)60367-8
- [237] Pan HH, Zhou XX, Zhao F et al. Diagnostic value of liquid-based cytology and smear cytology in pancreatic endoscopic ultrasound-guided fine needle aspiration: A meta-analysis. *World J Clin Cases* 2020; 8: 3006–3020 doi:10.12998/wjcc.v8.i14.3006
- [238] Burger M, Heidrich A, Petersen I et al. Increased accuracy of FNA-based cytological diagnosis of pancreatic lesions by use of an ethanol-based fixative system: A STROBE compliant study. *Medicine (Baltimore)* 2022; 101: e30449 doi:10.1097/MD.00000000000030449
- [239] Huang J, Liang Y, Xu L et al. Diagnostic efficacy of different pathologic methods for assessing tissue obtained by endoscopic ultrasound-guided fine needle aspiration: a prospective study. *Int J Clin Exp Pathol* 2021; 14: 34–44
- [240] Alvarez-Nava Torregro MT, Tasende JD, Campos AP et al. EUS-FNA of pancreatic cystic lesions: Should the endoscopic ultrasonographer learn to process the sample in the room? *Endosc Ultrasound* 2023; 12: 309–310
- [241] Wong N, Gwiti P, Murigu T et al. Cell block processing is optimal for assessing endoscopic ultrasound fine needle aspiration specimens of pancreatic mucinous cysts. *J Clin Pathol* 2020; 73: 102–106 doi:10.1136/jclinpath-2019-206079
- [242] Gan Q, Roy-Chowdhuri S, Duose DY et al. Adequacy evaluation and use of pancreatic adenocarcinoma specimens for next-generation sequencing acquired by endoscopic ultrasound-guided FNA and FNB. *Cancer Cytopathol* 2022; 130: 275–283 doi:10.1002/cncy.22533

- [243] Souza da Silva R, Pina MJ, Cirnes L et al. Comprehensive genomic studies on the cell blocks of pancreatic cancer. *Diagnostics (Basel)* 2024; 14: 906
- [244] Bunduc S, Varzaru B, Iacob RA et al. Endoscopic ultrasound-guided fine-needle aspiration pancreatic adenocarcinoma samples yield adequate DNA for next-generation sequencing: A cohort analysis. *World J Gastroenterol* 2023; 29: 2864–2874 doi:10.3748/wjg.v29.i18.2864
- [245] Mohamed WT, Jahagirdar V, Jaber F et al. Endoscopic ultrasound-guided fine-needle biopsy versus aspiration for tissue sampling adequacy for molecular testing in pancreatic ductal adenocarcinoma. *Cancers (Basel)* 2024; 16: 761 doi:10.3390/cancers16040761
- [246] Biermann K, Lozano Escario MD, Hebert-Magee S et al. How to prepare, handle, read, and improve EUS-FNA and fine-needle biopsy for solid pancreatic lesions: The pathologist's role. *Endosc Ultrasound* 2017; 6: S95–S98

Supplementary material

Endoscopic ultrasound-guided tissue sampling: European Society of Gastrointestinal Endoscopy (ESGE) Technical and Technology Review

Antonio Facciorusso, Marianna Arvanitakis, Stefano Francesco Crinò, Carlo Fabbri, Adele Fornelli, John Leeds, Livia Archibugi, Silvia Carrara, Jahnvi Dhar, Paraskevas Gkolfakis, Beate Haugk, Julio Iglesias-Garcia, Bertrand Napoleon, Ioannis S. Papanikolaou, Andrada Seicean, Pauline M. C. Stassen, Peter Vilmann, Tony C. Tham, Lorenzo Fuccio

Contents		Page
Table 1s	GRADE Quality of evidence interpretation	2
Table 2s	List of PICOs for the clinical questions	2
Table 3s	Literature search	5
Table 4s	Table of GRADE evidence	8
Table 5s	RCTs comparing CH-EUS-TA vs B mode EUS-TA for pancreatic masses	13
Figure 1s	Risk of bias assessment for PICO 1 (comparison between CH-EUS-TA and B mode EUS-TA for pancreatic masses)	14
Figure 2s	Forest plot concerning PICO 1 (comparison between CH-EUS-TA and B mode EUS-TA for pancreatic masses)	14
Table 6s	Studies assessing the diagnostic performance of FNB needles in autoimmune pancreatitis	15
Figure 3s	Forest plot assessing the diagnostic accuracy of FNB in autoimmune pancreatitis	17
Table 7s	RCTs comparing different methods for tissue sampling of subepithelial lesions	18
Table 8s	Studies comparing FNB vs FNA for tissue sampling of lymph nodes.	19
Figure 4s	Forest plot concerning the comparison between FNB vs FNA for tissue sampling of lymph nodes.	21
Table 9s	RCTs comparing the fanning vs the standard sampling technique for tissue sampling of pancreatic masses	22
Figure 5s	Forest plot comparing fanning vs standard FNA/B of pancreatic masses	23
Table 10s	RCTs comparing different sampling techniques for pancreatic masses	24
Table 11s	Studies comparing EUS-tissue sampling of pancreatic head solid lesions in patients with vs without biliary stent	25
Table 12s	Studies comparing EUS-FNB with vs without ROSE for tissue sampling of pancreatic masses	26
Table 13s	Meta-analyses published in the last 5 years assessing the diagnostic outcomes of cystic fluid analysis	27
Table 14s	Outcomes of the meta-analyses assessing the diagnostic performance of TTNB for pancreatic cystic lesions	28
Table 15s	Outcomes of the meta-analyses assessing the effectiveness of nCLE for patients with pancreatic cystic lesions	29
Table 16s	Studies comparing antibiotic prophylaxis vs no prophylaxis before EUS-FNA of pancreatic cystic lesions	30

Table 1s GRADE Quality of evidence interpretation

GRADE Quality of Evidence	Intepretation
High	Further research is VERY UNLIKELY to change our confidence in the estimate of effect
Moderate	Further research is LIKELY to have an impact on our confidence in the estimate of effect and MAY change the estimate
Low	Further research is VERY LIKELY to have an impact on our confidence in estimate of effect and is LIKELY to change the estimate
Very Low	Any estimate of effect is very uncertain

Table 2s List of PICOs for the clinical questions

PICO question no.	Population	Intervention	Comparator	Outcomes
1	Patients with pancreatic masses	CH-EUS-TA	B mode-EUS-TA	<ul style="list-style-type: none"> • Diagnostic accuracy
2	Patients with pancreatic masses	End-cutting FNB	FNA or reverse bevel FNB	<ul style="list-style-type: none"> • Diagnostic accuracy • Sample adequacy

3	Patients with autoimmune pancreatitis	EUS-FNB	--	<ul style="list-style-type: none"> • Diagnostic accuracy • Level 1 and 2 histological diagnosis • Rate of definitive histopathology
4	Patients with GI subepithelial lesions	EUS-FNB	EUS-FNA, MIAB, or bite-on-bite biopsy	<ul style="list-style-type: none"> • Diagnostic accuracy • Sample adequacy
5	Patients with lymphadenopathy	EUS-FNB	EUS-FNA	<ul style="list-style-type: none"> • Diagnostic accuracy • Sample adequacy
6	Patients with pancreatic masses	Fanning technique	Standard FNA/B	<ul style="list-style-type: none"> • Diagnostic accuracy
7	Patients with pancreatic masses	Wet suction	Dry suction, or slow-pull, or no stylet	<ul style="list-style-type: none"> • Sample adequacy • Tissue integrity rate • Bloodiness rate

8	Patients with pancreatic masses	Two or multiple passes	One pass	<ul style="list-style-type: none"> • Diagnostic accuracy • Sample adequacy
9	Patients with jaundice and a pancreatic head mass	EUS-TA after biliary stent	EUS-TA	<ul style="list-style-type: none"> • Diagnostic accuracy
10	Patients with pancreatic masses; Patients with subepithelial lesions	EUS-FNB with ROSE	EUS-FNB without ROSE	<ul style="list-style-type: none"> • Diagnostic accuracy • Sample adequacy
11	Patients with pancreatic masses	EUS-FNB with MOSE	EUS-FNB without MOSE	<ul style="list-style-type: none"> • Diagnostic accuracy • Sample adequacy
12	Patients with pancreatic cystic lesions	Cystic fluid glucose dosage	Cystic fluid CEA dosage	<ul style="list-style-type: none"> • Sensitivity • Specificity
13	Patients with pancreatic cystic lesions	EUS-TTNB	EUS-FNA with cytological analysis	<ul style="list-style-type: none"> • Diagnostic accuracy
14	Patients with pancreatic cystic lesions	CLE	EUS-FNA with cytological analysis	<ul style="list-style-type: none"> • Diagnostic accuracy
15	Patients with pancreatic cystic lesions undergoing EUS-FNA	Antibiotic prophylaxis	No antibiotic prophylaxis	<ul style="list-style-type: none"> • Infection rate

Table 3s Literature search

Searching on Pubmed	
Search number	Query
#1	EUS-guided OR fine-needle biopsy (FNB) AND random* Sort by: Most Recent " "EUS-guided"[MeSH Terms] OR ("EUS"[All Fields] AND "guided"[All Fields]) OR "EUS guided"[All Fields] EUS-guided: "eus guided"[MeSH Terms] OR ("eus"[All Fields] AND "guided"[All Fields]) OR "eus guided"[All Fields]
#2	("biopsy, fine needle"[MeSH Terms] OR ("biopsy"[All Fields] AND "fine needle"[All Fields]) OR "fine- needle biopsy"[All Fields] OR ("fine"[All Fields] AND "needle"[All Fields] AND "biopsy"[All Fields]) OR "fine needle biopsy"[All Fields]) AND "FNB"[All Fields]
Searching on Pubmed	
Search number	Query
#1	pancreatic cyst [MeSH Terms]
#2	"cyst pancreas"[Title/Abstract] OR "cystic pancreatic lesions "[Title/Abstract] OR "intraductal papillary mucinous neoplasm "[Title/Abstract] OR "mucinous cystic neoplasm"[Title/Abstract] OR "pancreatic cystic lesions"[Title/Abstract] OR "pancreatic cystic tumor"[Title/Abstract] OR "Pancreatic Intraductal Neoplasms"[Title/Abstract]
#3	"endoscopic ultrasound"[Title/Abstract] OR "diagnostic imaging"[Title/Abstract] OR "endoscopic ultrasound guided fine needle aspiration"[Title/Abstract] OR "EUS FNA"[Title/Abstract] OR "cyst fluid analysis"[Title/Abstract] OR "chemical analysis"[Title/Abstract] OR "tumor biomarker"[Title/Abstract] OR "tumor marker"[Title/Abstract] OR "carcinoembryonic antigen"[Title/Abstract] OR "CEA"[Title/Abstract] OR "glucose"[Title/Abstract] OR "intracystic glucose"[Title/Abstract] OR "pancreatic cyst fluid glucose"[Title/Abstract] OR "cytology"[Title/Abstract] OR "cytopathologic assessment"[Title/Abstract] OR "molecular marker"[Title/Abstract] OR "next generation sequencing"[Title/Abstract] OR "KRAS"[Title/Abstract] OR "GNAS"[Title/Abstract] OR "DNA mutation "[Title/Abstract] OR "Endoscopic ultrasound guided through the needle micro forceps"[Title/Abstract] OR "EUS TTNB"[Title/Abstract] OR "microforceps"[Title/Abstract] OR "microforceps biopsy"[Title/Abstract] OR "EUS MFB"[Title/Abstract] OR "forceps

	biopsy"[Title/Abstract] OR "fine needle biopsy"[Title/Abstract] OR "EUS FNB"[Title/Abstract] OR "micro forcep"[Title/Abstract] OR "moray micro forceps"[Title/Abstract] OR "through the needle"[Title/Abstract] OR "endomicroscopy"[Title/Abstract] OR "EUS guided needle based confocal laser endomicroscopy"[Title/Abstract] OR "EUS nCLE"[Title/Abstract] OR "contrast enhanced EUS"[Title/Abstract] OR "contrast enhanced harmonic EUS"[Title/Abstract] OR "CE EUS"[Title/Abstract] OR "CH EUS"[Title/Abstract] OR "CEH EUS"[Title/Abstract]
#4	(#1 OR #2) AND #3
Searching on Embase	
No.	Query
#1	'pancreatic cyst':ti,ab,kw OR 'cyst pancreas':ti,ab,kw OR 'cystic pancreatic lesions':ti,ab,kw OR 'intraductal papillary mucinous neoplasm':ti,ab,kw OR 'mucinous cystic neoplasm':ti,ab,kw OR 'pancreatic cystic lesions':ti,ab,kw OR 'pancreatic cystic tumor':ti,ab,kw OR 'pancreatic intraductal neoplasms':ti,ab,kw
#2	'pancreas cyst'/exp
#3	'endoscopic ultrasound':ti,ab,kw OR 'diagnostic imaging':ti,ab,kw OR 'endoscopic ultrasound guided fine needle aspiration':ti,ab,kw OR 'eus fna':ti,ab,kw OR 'cyst fluid analysis':ti,ab,kw OR 'chemical analysis':ti,ab,kw OR 'tumor biomarker':ti,ab,kw OR 'tumor marker':ti,ab,kw OR 'carcinoembryonic antigen':ti,ab,kw OR 'cea':ti,ab,kw OR 'glucose':ti,ab,kw OR 'intracystic glucose':ti,ab,kw OR 'pancreatic cyst fluid glucose':ti,ab,kw OR 'amylase':ti,ab,kw OR 'cytology':ti,ab,kw OR 'cytopathologic assessment':ti,ab,kw OR 'molecular marker':ti,ab,kw OR 'next generation sequencing':ti,ab,kw OR 'kras':ti,ab,kw OR 'gnas':ti,ab,kw OR 'dna mutation':ti,ab,kw OR 'endoscopic ultrasound guided through the needle microforceps':ti,ab,kw OR 'eus ttnb':ti,ab,kw OR 'microforceps':ti,ab,kw OR 'microforceps biopsy':ti,ab,kw OR 'eus mfb':ti,ab,kw OR 'forceps biopsy':ti,ab,kw OR 'fine needle biopsy':ti,ab,kw OR 'eus fnb':ti,ab,kw OR 'micro forcep':ti,ab,kw OR 'moray micro forceps':ti,ab,kw OR 'through the needle':ti,ab,kw OR 'endomicroscopy':ti,ab,kw OR 'eus guided needle based confocal laser endomicroscopy':ti,ab,kw OR 'eus ncle':ti,ab,kw OR 'contrast enhanced eus':ti,ab,kw OR 'contrast enhanced harmonic eus':ti,ab,kw OR 'ce eus':ti,ab,kw OR 'ch eus':ti,ab,kw OR 'ceh eus':ti,ab,kw
#4	(#1 OR #2) AND #3
#5	#4 AND 'Article'/it
Searching on Cochrane	
ID	Search
#1	('pancreas cyst' OR 'cyst pancreas' OR 'cystic pancreatic lesions ' OR 'intraductal papillary mucinous neoplasm ' OR 'mucinous cystic neoplasm' OR 'pancreatic cystic lesions' OR 'pancreatic cystic tumor' OR 'Pancreatic Intraductal Neoplasms'):ti,ab,kw

#2	MeSH descriptor: [Pancreatic Cyst] explode all trees
#3	'endoscopic ultrasound' OR 'diagnostic imaging' OR 'endoscopic ultrasound guided fine needle aspiration' OR 'EUS FNA' OR 'cyst fluid analysis' OR 'chemical analysis' OR 'tumor biomarker' OR 'tumor marker' OR 'carcinoembryonic antigen' OR 'CEA' OR 'glucose' OR 'intracystic glucose' OR 'pancreatic cyst fluid glucose' OR 'amylase' OR 'cytology' OR 'cytopathologic assessment' OR 'molecular marker' OR 'next generation sequencing' OR 'KRAS' OR 'GNAS' OR 'DNA mutation' OR 'Endoscopic ultrasound guided through the needle microforceps' OR 'EUS TTNB' OR 'microforceps' OR 'microforceps biopsy' OR 'EUS MFB' OR 'forceps biopsy' OR 'fine needle biopsy' OR 'EUS FNB' OR 'micro forcep' OR 'moray micro forceps' OR 'through the needle' OR 'endomicroscopy' OR 'EUS guided needle based confocal laser endomicroscopy' OR 'EUS nCLE' OR 'contrast enhanced EUS' OR 'contrast enhanced harmonic EUS' OR 'CE EUS' OR 'CH EUS' OR 'CEH EUS'
#4	(#1 OR #2) AND #3

Table 4s Table of GRADE evidence

Certainty assessment								Effect estimate	Certainty	Comments
PICO	No. of studies	Study design	Risk of bias	Inconsistency	Indirectness	Imprecision	Publication bias			
1	4	RCTs	Low	No	Yes	Yes	No	RR 0.99 (0.95-1.03)	⊕⊕○○○ Low	Imprecision due to CIs crossing unity and indirectness related to different contrast agents and needles used
2	19	RCTs	Low	No	No	No	No	Franseen vs reverse bevel: RR 1.21 (1.05-1.40) Franseen vs FNA: RR 1.21 (1.01-1.25) Fork-tip vs reverse bevel: RR 1.17 (1.03-1.33) Fork-tip vs FNA: RR	⊕⊕⊕⊕⊕ High	Results from a network meta-analysis

								1.09 (1.01-1.19)		
3	12	Observational Studies	High	High	High	Low	Low	Pooled accuracy: End-cutting FNB: 80% (70%-90%) Reverse bevel FNB: 49 (21%-67%)	○○○○○ Very Low	Based on observational studies, indirect comparison, high heterogeneity
4	8	RCTs	Low	Low	Low	High	Low	Accuracy FNB vs FNA: RR 1.33 (1.02-1.72) MIAB vs FNA: 1.20 (0.90-1.62)	⊕⊕⊕○ Moderate	Imprecision due to wide CIs crossing the unity or failure to reach the optimal information size
5	10	Observational studies	High	High	Low	High	Low	OR 1.49 (0.89-2.49)	○○○○○ Very Low	Based on observational studies, risk of bias in the literature, high heterogeneity and imprecision
6	4	RCTs	Low	Low	High	Low	Low	RR 1.21 (1.11-1.31)	⊕⊕⊕○ Moderate	High indirectness due to different

										sampling techniques
7	10	RCTs	Low	Low	High	Low	Low	No stylet vs slow-pull RR 0.85, 0.078-0.92; no stylet vs dry suction RR 0.85, 0.78-0.92; no stylet vs wet suction RR 0.83, 0.76-0.90	⊕⊕⊕⊕○ Moderate	High indirectness due to different study design and different needles used
8	19	RCTs	Low	Low	High	Low	Low	Two vs one pass: OR 1.80 (1.23-2.63) Three vs two passes: OR 1.43 (0.92-2.23)	⊕⊕⊕⊕○ Moderate	High indirectness due to different availability of ROSE or MOSE
9	7	Retrospective	Low	Low	Low	Low	Low	OR 0.54, 0.17-0.97)	⊕○○○○ Low	Based on retrospective non-randomized studies
10	2	RCTs	Low	Low	High	Low	Low	OR 1.13, 0.33-3.92	⊕⊕⊕⊕○ Moderate	High indirectness due to different study design and different

										FNB needles used
11	1	RCT	Low	Not assessable	Low	High	Low	RR 1.02 (0.95-1.10)	⊕⊕⊕⊕○ Moderate	High imprecision due to wide CIs crossing the unity and failure to reach the optimal information size
12	8	Retrospective	Low	Low	Low	Low	Low	Diagnostic OR: Glucose 92 (30-208) CEA 82 (6-1101)	⊕○○○○○ Low	Based on non-randomized studies
13	3	Retrospective	High	Low	Low	High	Low	OR 3.44 (1.32-8.96)	○○○○○○○ Very Low	High imprecision due to the failure to reach the optimal information size
14	7	Retrospective	Low	Low	Low	Low	Low	OR 3.94 (1.58-9.82)	⊕○○○○○ Low	Based on non-randomized studies
15	1	RCT	Low	Not applicable	Low	High	Low	OR 0.34 (0.01-8.34)	⊕⊕⊕⊕○ Moderate	High imprecision due to wide CIs crossing the unity and the failure to

										reach the optimal information size
--	--	--	--	--	--	--	--	--	--	------------------------------------

Table 5s RCTs comparing CH-EUS guided tissue acquisition vs B mode EUS-guided tissue acquisition for pancreatic masses

Study (Author, year)	Country	Study design	No. of patients	Age (y)	Male sex (%)	Needle used	Contrast used	Accuracy	Adequacy
Sugimoto 2015	Japan	Parallel RCT	CH-EUS: 20 EUS: 20	69.5±10.5 67.1±9.9	7 (35) 8 (40)	22,25 FNA	Sonazoid	18/20 17/20	20/20 20/20
Seicean 2020	Romania	Cross-over RCT	CH-EUS: 148 EUS: 148	64.5±11.3	84 (56.8)	22 FNA	Sonovue	132/148 131/148	NR NR
Cho 2021	Korea	Parallel RCT	CH-EUS: 120 EUS: 120	66.3±11.7 68.3±11.9	64 (53.3) 63 (52.5)	19,25 FNA/FNB (reverse bevel)	Sonovue	103/120 106/120	NR NR
Kuo 2023	Taiwan	Parallel RCT	CH-EUS: 59 EUS: 59	64.7±11.6 64.1±12.6	34 (57.6) 38 (64.4)	22 FNB (Franseen)	Sonazoid	58/59 59/59	57/59 56/59
Abbreviations: CH-EUS: contrast harmonic endoscopic ultrasound; EUS: endoscopic ultrasound; FNA; fine needle aspiration; FNB, fine needle biopsy; RCT, randomized controlled trial									

Figure 1s Risk of bias assessment for PICO 1 (comparison between CH-EUS guided tissue acquisition and B mode EUS-guided tissue acquisition for pancreatic masses)

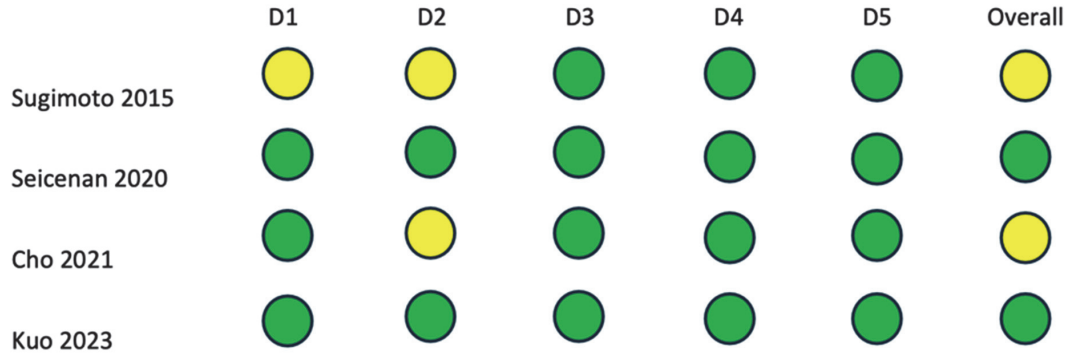

Figure 2s Forest plot concerning PICO 1 (comparison between CH-EUS guided tissue acquisition and B mode EUS-guided tissue acquisition for pancreatic masses)

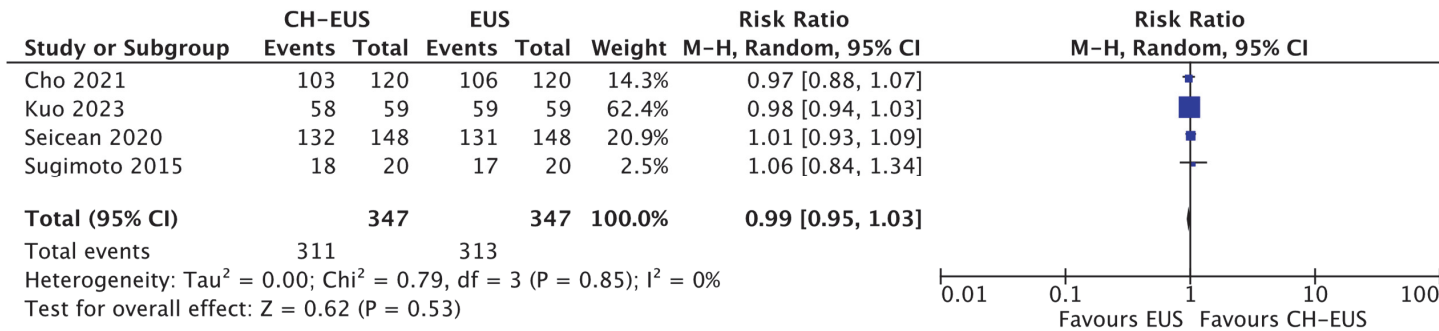


Table 6s Studies assessing the diagnostic performance of FNB needles in autoimmune pancreatitis

Study (Author, year)	Country	Study design	No. of patients	Age (y)	Male sex (%)	ROSE	Accuracy	Adequacy	ICDC 1/2 criteria
Jung 2015	Korea	Retrospective	22 Reverse bevel FNB: 20	54.7±15.3	49 (79)	No	14/20	NR	NR
Kurita 2020	Japan	Parallel RCT	22 Franseen: 50	70 (21-86)	40 (73)	No	39/50	44/50	28/11
			20 Forward facing bevel: 51	68 (21-86)	39 (71)		23/50	34/50	13/10
Lee 2017	Korea	Retrospective	19 FNB: 15	NR	NR	No	11/15	15/15	NR
			22 reverse bevel: 42				21/42	31/42	
Tsutsumi 2021	Japan	Retrospective	21 Sonopsy: 14	71 (50-79)	11 (78.5)	No	9/14	14/14	5/4
Zator 2018	USA	Retrospective	19/22/25 end-cutting/reverse bevel: 29	54	21 (72)	No	23/29	NR	18/3
Ishikawa 2020	Japan	Prospective	22 Franseen: 56	66.7±11.6	41 (73.2)	No	51/56	56/56	32/19
Oppong 2020	UK	Retrospective	Fork-tip: 18	62.2±11.4	17 (71)	No	14/18	17/18	13/1
			Reverse bevel: 6						
Noguchi 2020	Japan	Retrospective	22 Franseen/20 forward facing bevel: 32	68 (17-83)	56.6%	No	17/32	NR	10/7
Thomsen 2022	Denmark	Retrospective	22 Fork-tip: 19	NR	11 (57.8)	No	15/19	19/19	9/7
Notohara 2020	Japan	Retrospective	22 Franseen: 27 20 forward bevel/19-22 end-cutting:58	65±9	69 (81.1)	No	74/85	74/85	22/23
Ishikawa 2024	Japan	Prospective	19 Franseen: 20	68 (60-71)	12 (60)	No	18/20	20/20	13/3

Conti Bellocchi 2023	Italy	Prospective	22 Franseen: 7 22 Fork-tip: 32	56.6±18.3	31 (79.5)	No	6/7 30/32	7/7 32/32	25/11
Abbreviations: FNA; fine needle aspiration; FNB, fine needle biopsy; RCT, randomized controlled trial; ROSE; Rapid On-Site Evaluation									

Figure 3s Forest plot assessing the diagnostic accuracy of FNB in autoimmune pancreatitis

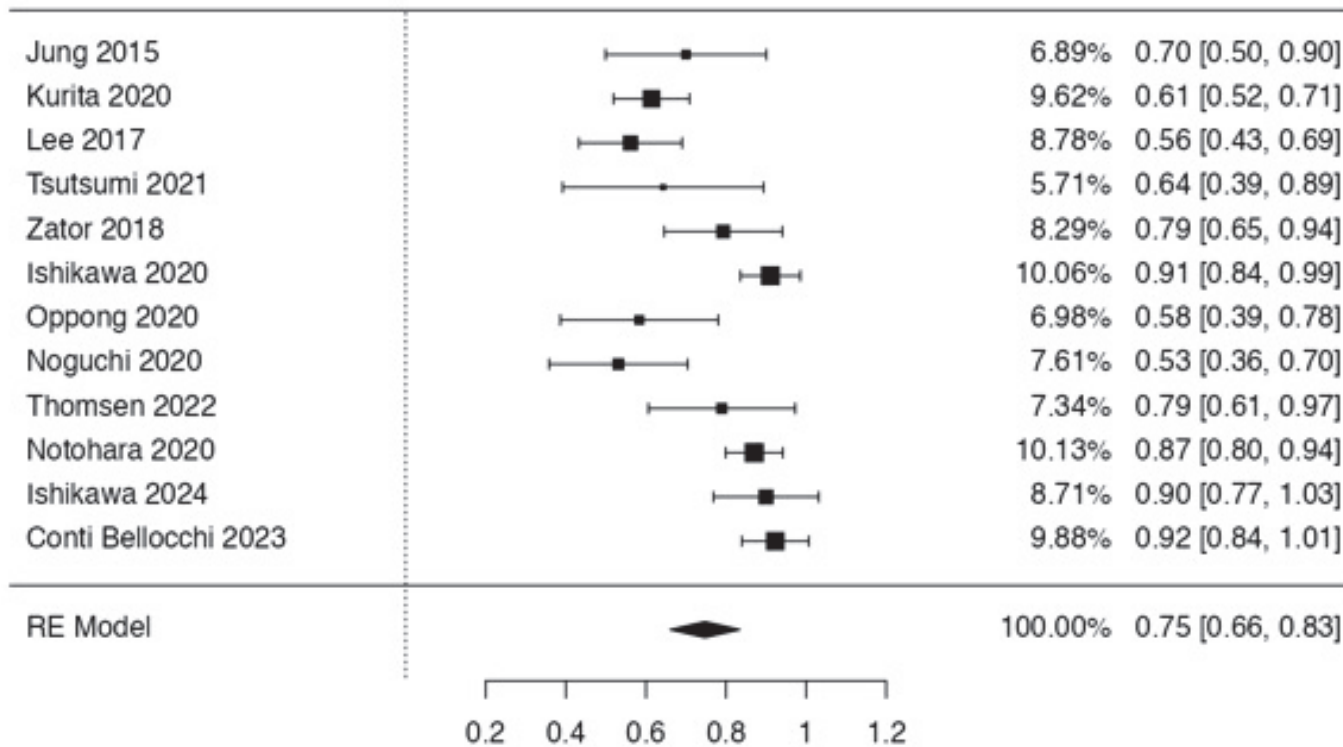


Table 7s RCTs comparing different methods for tissue sampling of subepithelial lesions

Study (Author, year)	Country	Study design	No. of patients	Age (y)	Male sex (%)	Needle/technique used	ROSE	Accuracy	Adequacy
Osegawa 2019	Japan	Parallel RCT	MIAB: 23 EUS-FNA: 24	65.6±10.3 58.3±14.2	6 (26.1) 13 (54.2)	22,25 FNA	Yes	21/23 17/24	21/23 18/24
Han 2016	Korea	Cross-over RCT	EUS-FNB: 22 EUS-FNA: 22	59.5 (44.2-67.5)	10 (45.5)	22 reverse bevel FNB 22 FNA	Yes	18/22 15/22	21/22 20/22
Sanaei 2020	USA/Spain/Italy	Parallel RCT	MIAB: 30 EUS-FNA: 26	66.6±13.4 68.7±11.9	16 (53.3) 15 (57.7)	SINK 22 reverse bevel FNB	No	25/30 19/26	26/30 20/26
Zoundjekpon 2020	Czech Republic	Parallel RCT	MIAB: 22 EUS-FNA: 24	30-81 47-83	11 (50) 10 (41.6)	KHB 22 FNA	No	19/22 22/24	20/22 22/24
Wong 2022	Taiwan	Parallel RCT	MIAB: 20 Bite-on-bite: 20	62.7±9.1 58.3±7.3	6 (30) 8 (40)	SINK Standard forceps	No	17/20 10/20	17/20 10/20
Iwai 2018	Japan	Cross-over RCT	EUS-FNB: 23 EUS-FNA: 23	64.3 (35-78)	8 (34.7)	19/22 reverse bevel FNB 19/22 FNA	No	21/23 17/23	22/23 18/23
Kim 2014	Korea	Parallel RCT	EUS-FNB: 12 EUS-FNA: 10	60±16.2 51±11.5	4 (33) 6 (60)	22 reverse bevel FNB 22 FNA	No	9/12 2/10	11/12 3/10
Hedenstrom 2018	Sweden	Cross-over RCT	EUS-FNB: 70 EUS-FNA: 70	68 (28-92)	41 (58.5)	19/22 reverse bevel FNB 22/25 FNA	In 64% of patients	58/70 34/70	63/70 44/70
Abbreviations: EUS: endoscopic ultrasound; FNA; fine needle aspiration; FNB, fine needle biopsy; KHB, Key Hole biopsy; MIAB, mucosal incision assisted biopsy; RCT, randomized controlled trial; ROSE, rapid on-site cytological evaluation; SINK, single incision needle knife biopsy									

Table 8s Studies comparing FNB vs FNA for tissue sampling of lymph nodes

Study (Author, year)	Country	Study design	No. of patients	Age (y)	Male sex (%)	Needle used	ROSE	Accuracy	Adequacy
Bang 2019	USA	Retrospective	EUS-FNB: 88	67.1±12.9	54%	22 Franseen/Fork-tip FNB 22/25 FNA	Yes	NR	88/88
			EUS-FNA: 264	65.8±13.7	56.7%				258/264
Chin 2017	Spain	Retrospective	EUS-FNB: 105	63.8±15	117 (69.6)	19/20/22/25 reverse bevel FNB 19/22/25 FNA	No	92/105	NR
			EUS-FNA: 63						55/63
De Moura 2020	USA	Retrospective	EUS-FNB: 101	62.9±13.2	61 (60.4)	20/22/25 Franseen/Fork-tip/reverse bevel 22/25 FNA	In 17.8%	84 /101	NR
			EUS-FNA: 108	64.4±11.7	81 (75)				In 16.6%
Facciorusso 2021	Italy/India/Colombia	Retrospective	EUS-FNB: 105	64.4±7	67 (63.8)	22/25 Franseen/Fork-tip/reverse bevel 22/25 FNA	No	92/105	101/105
			EUS-FNA: 105	64.6±5	68 (64.7)				55/63
Hedenstrom 2021	Sweden	Cross-over RCT	EUS-FNB: 48	69 (59-76)	24 (50)	22 reverse bevel FNB 25 FNA	In 79.1%	34/48	NR
			EUS-FNA: 48						31/48
Hucl 2013	India	Cross-over RCT	EUS-FNB: 76	45.1±14.2	43 (56.5)	22 reverse bevel FNB 22 FNA	No	51/76	61/76
			EUS-FNA: 76						61/76
Nagula 2018	USA	Parallel RCT	EUS-FNB: 18	67.8±12.7	53.2%	22/25 reverse bevel FNB 22/25 FNA	In 82%	NR	17/18
			EUS-FNA: 28	65.2±13.2	51.1%				26/28
Sterlacci 2016	Germany	Cross-over RCT	EUS-FNB: 13	68±12	51.8%	22 reverse bevel FNB 22 FNA	No	12/13	13/13
			EUS-FNA: 13						11/13
Tanisaka 2021	Japan	Retrospective	EUS-FNB: 71	70 (61-74)	36 (50.7)	Franseen FNA	No	68/71	71/71
			EUS-FNA: 83	67 (60-74)	51 (61.4)				73/83
Yang 2023	China	Retrospective	EUS-FNB: 23	54.7±17.5	12 (55)	20/22 Franseen/reverse bevel FNB 22/25 FNA	No	21/23	NR
			EUS-FNA: 30	51.9±16.6	13 (42)				18/30

Abbreviations: EUS: endoscopic ultrasound; FNA; fine needle aspiration; FNB, fine needle biopsy; NR, not reported; RCT, randomized controlled trial; ROSE, rapid on-site cytological evaluation;

Figure 4s Forest plot concerning the comparison between FNB vs FNA for tissue sampling of lymph nodes

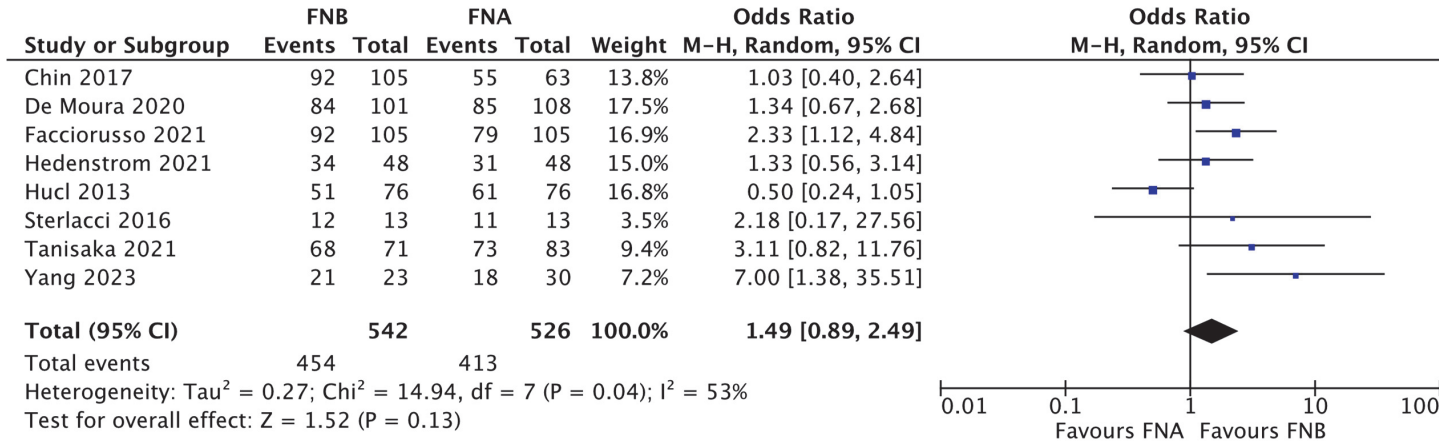
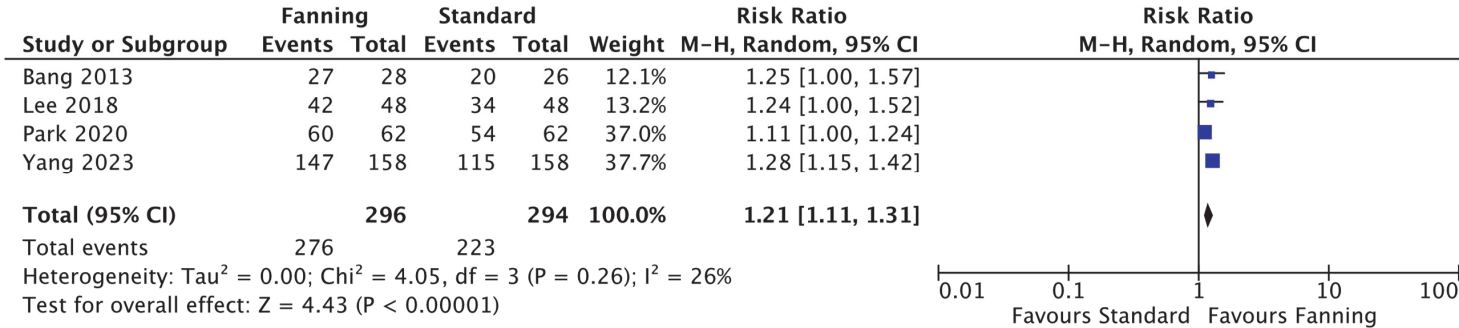


Table 9s RCTs comparing the fanning vs the standard sampling technique for tissue sampling of pancreatic masses

Study (Author, year)	Country	Study design	No. of patients	Age (y)	Male sex (%)	Needle/technique used	ROSE	Accuracy	Adequacy
Bang 2013	USA	Parallel RCT	Fanning: 28 Standard: 26	64.4±11.1 63.4±10.8	13 (46.4) 13 (50)	22,25 FNA	Yes	27/28 20/26	27/28 20/26
Lee 2018	Korea	Cross-over RCT	Fanning: 48 Standard: 48	68.1±11.9	29 (60)	22 FNA	No	42/48 34/48	46/48 48/48
Park 2020	Korea	Parallel RCT	Torque: 62 Standard: 62	62.7±12.8 63.3±12.4	40 (64.5) 35 (56.5)	22/25 reverse bevel FNB	No	60 /62 54/62	62/62 62/62
Yang 2023	Korea	Cross-over RCT	Fanning: 158 Torque: 158 Standard: 158	67.6±10.6	101 (63.5)	22 Franseen FNB	No	147/158 149/158 115/158	NR
Kuo 2023	Taiwan	Parallel RCT	Fanning: 59 CH-EUS-FNB: 59	64.1±12.6 64.7±11.6	38 (64.4) 34 (57.6)	22 Franseen FNB	Yes	59/59 58/59	NR
Abbreviations: CH, Contrast Harmonic; EUS: endoscopic ultrasound; FNA; fine needle aspiration; FNB, fine needle biopsy; NT, not reported; RCT, randomized controlled trial; ROSE, rapid on-site cytological evaluation;									

Figure 5s Forest plot comparing fanning vs standard FNA/B of pancreatic masses

A. Including torque



B. Excluding torque

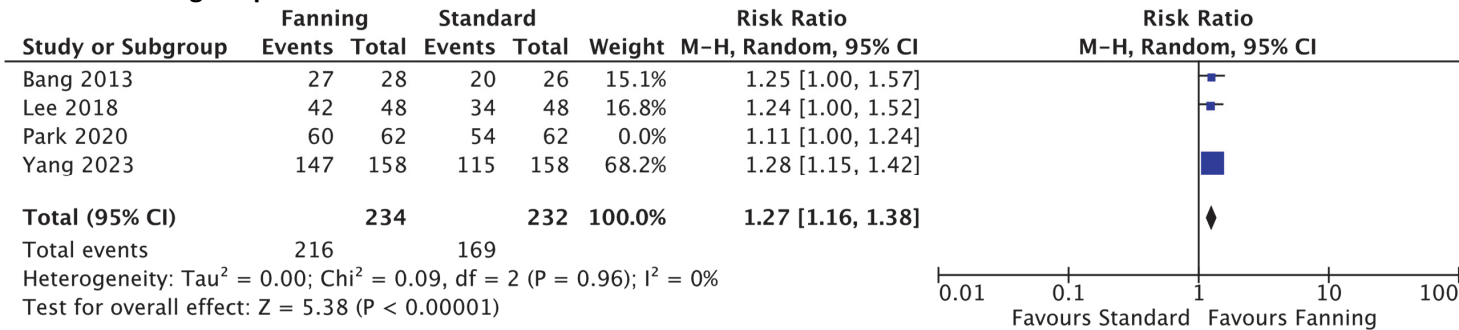


Table 10s RCTs comparing different sampling techniques for pancreatic masses

Study (Author, year)	Country	Study design	No. of patients	Age (y)	Male sex (%)	Needle used	ROSE	Adequacy	Bloodiness rate	Tissue integrity
Bang 2021	USA	Cross-over RCT	Dry suction: 129 Slow pull: 129 No suction: 129	69.8±9.9	68 (52.7)	22Fransen/22Fork-tip /21 Menghini-tip/22 reverse bevel FNB	No	124/129 119/129 102/129	102/129 80/129 56/129	35/129 54/129 61/129
Crino 2022	Multicenter	Cross-over RCT	Wet suction: 146 Slow pull: 146	65.9±11.3	54.3%	22 Franseen/22Fork-tip	No	140/146 138/146	85/146 54/146	108/146 99/146
Lin 2022	Taiwan	Cross-over RCT	Dry suction: 50 Wet suction: 50	63.5±9.86	32 (64)	20 forward bevel	No	NR	79/100 specimen 58/100 specimen	NR
Zhou 2021	China	Parallel RCT	Dry suction: 60 Slow pull: 56	58 (51-64) 61.5 (52.66)	43 (71.7) 35 (62.5)	22 reverse bevel	No	60/60 56/56	NR	32/60 27/56
Costa-Moreira 2021	Portugal	Cross-over RCT	Dry suction: 50 No suction: 50	65.5±11.8	23 (46)	22 Franseen	No	39/50 36/50	14/50 9/50	NR
Di Mitri 2020	Italy	Parallel RCT	Dry suction: 55 Slow pull: 55	70.8±10.7 70.9±10.1	24 (44) 25 (45)	20 forward bevel	No	43/55 41/55	14/55 11/55	NR
Tong 2021	China	Cross over RCT	Dry suction: 50 Wet suction: 50	60 (49-67.2)	34 (68)	22 reverse bevel	No	44/50 49/50	32/50 27/50	27/50 39/50
Mendoza-Ladd 2022	USA	Parallel RCT	Dry suction: 20 Wet suction: 17 Slow pull: 18	63.8±14.4 69.1±13.2 65.6±10.2	13 (65) 7 (41) 12 (67)	22 Franseen/22 Fork-tip	Yes	20/20 17/17 18/18	1/20 0/17 0/18	1/20 0/17 2/18
Lee 2019	Japan	Cross over RCT	Slow pull: 50 Dry suction: 50 No suction: 50	66.78±12.6	27 (54)	22 reverse bevel	No	45/50 40/50 38/50	15/50 21/50 5/50	NR
Delgado-Cortes 2023	Mexico	Cross over RCT	Dry suction: 75 Slow pull: 75 Wet suction: 75	63 (55-72)	39 (52)	22 Franseen	No	68/75 72/75 65/75	1.55± 0.92 2.08±0.8 1.99± 0.83	3.95± 1.28 3.67± 1.51 4.09± 1.43

Abbreviations: NR, not reported; RCT, randomized controlled trial; ROSE, rapid on-site cytological evaluation

Table 11s Studies comparing EUS-tissue sampling of pancreatic head solid lesions in patients with vs without biliary stent

Study (Author, year)	Country	Study design	No. of patients	Age (y)	Male sex (%)	Needle	Type of stent	ROSE	Adequacy	Accuracy
Crino 2021	Italy	Retrospective	Stent: 347 No stent: 495	68 (57.5-76) 70 (64-78)	202 (58.2) 271 (58.8)	Reverse bevel, end-cutting FNB	62.5% plastic, 37.5% metal	11.8% 14.1%	NR	300/347 456/495
Antonini 2017	Italy	Retrospective	Stent: 56 No stent: 74	69±9.9 70.3±10.3	33 (58.9) 46 (62.2)	Reverse bevel FNB	Plastic	28.5% 18.9%	54/56 67/74	50/56 64/74
Bekkali 2018	UK	Retrospective	Stent: 294 No stent: 287	66.3±9.4 65±11.4	160 (54.4) 185 (64.4)	Reverse bevel, Fork-Tip FNB	46.6% plastic, 53.4% metal	21.7% 13.3%	274/294 266/287	226/294 223/287
Fisher 2011	USA	Retrospective	Stent: 98 No stent: 170	69.2 68.2	44.8% 44.7%	FNA	67.3% plastic, 6.1% metal	100% 100%	88/98 158/170	NR
Kim 2015	USA	Retrospective	Stent: 75 No Stent: 105	65±12	108 (60)	FNA, reverse bevel FNB	85.3% plastic, 14.7% metal	45%	NR	58/75 93/105
Ranney 2012	USA	Retrospective	Stent: 150 No stent: 64	68 (58-75) 69 (63-78)	105 (49) 32 (50)	FNA	70% plastic, 30% metal	100% 100%	143/150 60/64	143/150 60/64
Constantinescu 2022	Romania	Retrospective	Stent: 68 No stent: 175	62.6±12.23 61.9±12.83	40 (58.8) 98 (56)	FNA, reverse bevel FNA, Franseen FNB	85.3% plastic, 14.7% metal	0% 0%	NR	58/68 157/175

Abbreviations: FNA, fine-needle aspiration; FNB, fine-needle biopsy; NR, not reported; ROSE, rapid on-site cytological evaluation;

Table 12s Studies comparing EUS-FNB with vs without ROSE for tissue sampling of pancreatic masses

Study (Author, year)	Country	Study design	No. of patients	Age (y)	Male sex (%)	Needle	Sampling technique	Accuracy	Adequacy
Crino 2021	Multicenter	Parallel RCT	ROSE: 385 No ROSE: 386	67.5±11.6 67.3±11.4	225 (58.4) 210 (54.4)	20 forward bevel, 22 Franseen/Fork-tip	Dry Suction or slow pull	371/385 376/386	364/385 372/386
De Moura 2020	USA	Retrospective	ROSE: 129 No ROSE: 249	Overall: 66.9±12.2	Overall: 198 (52.1)	22/25 reverse bevel/Franseen/Fork-tip	NR	121/129 201/249	NR
Fabbri 2017	Italy	Retrospective	ROSE: 140 No ROSE: 193	65.3±12.5 66.8±11.7	83 (59.3) 117 (60.6)	19/22/25 reverse bevel	NR	129 /140 170/193	129/140 170/193
Gines 2021	Spain, Italy	Prospective	ROSE: 40 No ROSE: 35	Overall: 65±13	Overall: 38 (51)	19 Menghini-tip	Dry Suction	NR	35/40 32/35
Soto Solis 2020	Mexico	Retrospective	ROSE: 13 No ROSE: 10	60 (47-77) 58 (46-72)	7 (53.8) 4 (40)	22 FNB	Slow pull	11/13 2/10	13/13 5/10
Nagula 2017	USA	Subgroup analysis of an RCT	ROSE: 114 No ROSE: 25	Overall: 67.8±12.7	Overall: 74 (53.2)	Reverse bevel	Slow pull	NR	103/114 20/25
Mahmood 2017	USA	Retrospective	ROSE: 91 No ROSE: 13	Overall: 61±20	Overall: 63 (61)	Fork-tip	NR	NR	89/91 9/13
Fitzpatrick 2020	USA	Retrospective	ROSE: 245 No ROSE: 79	Overall: 66±13.5	Overall: 176 (56)	Fork-tip	NR	239/245 70/79	233/245 70/79

Abbreviations: NT, not reported; RCT, randomized controlled trial; ROSE, rapid on-site cytological evaluation;

Table 13s Meta-analyses published in the last 5 years assessing the diagnostic outcomes of cystic fluid analysis

Study (Author, year)	Country	Study design	No. of studies	Test	Number of patients	Cut-off	Sensitivity diagnosis mucinous cyst	Specificity diagnosis mucinous cyst
Mohan 2022	USA/Italy	Meta-analysis	7	Glucose	566	50 mg/dL	90.1% (87.2%-92.5%)	85.3% (76.8%-91.1%)
Khan 2022	USA	Meta-analysis	15	CEA	2063	192 ng/mL	60.4% (57.7%-62.9%)	88.6% (85.9%-90.9%)
McCarty 2021	USA	Meta-analysis	8	Glucose CEA	609	50 mg/dL 192 ng/mL	91% (88%-94%) 56% (46%-66%)	86% (81%-90%) 96% (90%-99%)
Faias 2021	Portugal	Meta-analysis	31 4	CEA Glucose	5268 345	192 ng/mL 50 mg/dL	67% (65%-70%) 90% (85%-94%)	80% (76%-83%) 82% (72%-89%)
McCarty 2021	USA	Meta-analysis	6	KRAS and GNAS mutations	785	Not applicable	94% (72%-99%)	91% (72%-98%)
Guzman-Calderon 2022	Spain	Meta-analysis	6	Glucose	506	50 mg/dL	91% (88%-93%)	85% (81%-87%)
Pfluger 2023*	USA	Meta-analysis	6 10 2 3	KRAS/GNAS CEA Glucose MUC5AC	1360 1676 218 150	 192 ng/mL 50 mg/dL	 79% (70%-88%) 58% (45%-71%) 93% (89%-96%) 86% (76%-97%)	 98% (96%-100%) 87% (82%-92%) 76% (59%-93%) 92% (74%-100%)
Abbreviations: CEA, carcinoembryonic antigen								
<ul style="list-style-type: none"> All patients underwent surgery 								

Table 14s Outcomes of the meta-analyses assessing the diagnostic performance of TTNB for pancreatic cystic lesions

Study (Author, year)	Country	Study design	No. of studies	Number of patients	Technical success	Adequacy	Accuracy TTNB	Accuracy Cytology (absolute rate or OR TTNB/Cytology)	AE rate
Tacelli 2020	Italy	Meta-analysis	9	454	98.5% (97.3%-99.6%)	86.7% (80.1%-93.4%)	69.5% (59.2%-79.7%)	28.7% (15.7%-41.6%)	8.6% (4%-13.1%)
Facciorusso 2020	Italy	Meta-analysis	11	490	NR	85.3% (78.2%-92.5%)	78.8% (73.4%-84.2%)	OR 3.44 (1.32-8.96)	6%
Westerveld 2020	USA	Meta-analysis	8	426	98.2% (96.8%-99.3%)	NR	72.5% (60.6%-83%)	38.1% (18%-60.5%) OR 9.37 (5.69-15.42)	7% (2.3%-14.1%)
McCarty 2020	USA	Meta-analysis	11	518	97.1% (93.7%-98.7%)	79.60 % (72.6%-85.1%)	82.7 % (77.8%-86.8%)	OR 8.7 (1.1-67.1)	8.26 % (4.4%-15%)
Rift 2021	Denmark	Meta-analysis	10	99	NR	NR	86% (62%-96%)	NR	NR
Kovacevic 2021	Denmark/Italy	Meta-analysis	12	Overall: 1023	94% (88%-98%)	NR	74% (69%-78%)	NR	5% (2%-8%)
Gopakumar 2024	USA	Meta-analysis	11	575	NR	Sensitivity: 76.6% (72.6%-80.3%)	Specificity: 98.9% (93.8%-100%)	NR	3.04% (1.83%-4.54%)
Abbreviations: AE, adverse event; OR, Odds Ratio; TTNB, through-the-needle biopsy;									

Table 15s Outcomes of the meta-analyses assessing the effectiveness of nCLE for patients with pancreatic cystic lesions

Study (Author, year)	Country	Study design	No. of studies	Number of patients	Accuracy	Sensitivity	Specificity	OR accuracy compared to EUS-FNA	AE rate
Facciorusso 2020	Italy	Meta-analysis	10	536	88.6% (83.7%-93.4%)	82.4% (74.7%-90.1%)	96.6% (94.3%-99%)	3.94 (1.58-9.82)	NR
Konjeti 2022	USA	Meta-analysis	7	324	99% (98%-100%)	85% (71%-93%)	99% (90%-100%)	NR	1% (0%-3%)
Saghir 2022	USA	Meta-analysis	11	443	93% (79%-87%)	85.3% (76.9%-93.7%)	90.5% (82.2%-98.7%)	NR	5.41%
Kovacevic 2021	Denmark/Italy	Meta-analysis	9	469	85% (82%-88%)	86% (69%-94%)	83% (62%-94%)	NR	3% (1%-5%)
Wang 2022	China	Meta-analysis	10	547	NR	90% (83%-94%)	96% (75%-99%)	NR	2.7%
Abbreviations: AE, adverse event; EUS, Endoscopic Ultrasound; FNA, Fine-needle aspiration; OR, Odds Ratio									

Table 16s Studies comparing antibiotic prophylaxis vs no prophylaxis before EUS-FNA of pancreatic cystic lesions

Study (Author, year)	Country	Study design	Number of patients	Age	Sex male (%)	Antibiotic regimen	Infection rate	Severe infection rate	OR infection rate
Baldrinath 2019	USA	Retrospective	Prophylaxis: 89 Control: 121	65	96 (45.7%)	NR	1/89 0/121	NR	4.12 (0.17-102.29)
Colan-Hernandez 2020	Spain	Parallel RCT	Prophylaxis: 112 Control: 114	64±12 65±13	55 (59.1) 48 (42.1)	Ciprofloxacin 200 mg before FNA, followed by 7 doses of ciprofloxacin 500 mg every 12 h	0/112 1/114	0/112 1/114	0.34 (0.01-8.34)
Facciorusso 2019	Italy	Retrospective	Prophylaxis: 135 Control: 135	64 (61-70) 64 (62-68)	72 (53.3) 70 (51.8)	Ciprofloxacin 200 mg followed by 3-5 days of oral ciprofloxacin	2/135 3/135	0/135 1/135	0.66 (0.11-4.02)
Guarner-Argente 2019	USA	Retrospective	Prophylaxis: 88 Control: 178	65±15 63±14	44 (50) 74 (42)	Levofloxacin in 78 pts	2/88 1/178	1/86 0/172	4.12 (0.37-46.03)
Lee 2005	USA	Retrospective	Prophylaxis: 543 Control: 60	63±0.6	229 (38)	Fluoroquinolone for 3 days	1/543 0/60	NR	0.33 (0.01-8.30)
Lee 2017	USA	Retrospective	Prophylaxis: 71 Control: 60	62±12.6	326 (52.1)	NR	2/71 7/60	NR	0.22 (0.04-1.10)
Abbreviations: OR, Odds Ratio; NR, Not Reported									