

Advanced imaging for detection and differentiation of colorectal neoplasia: European Society of Gastrointestinal Endoscopy (ESGE) Guideline



Authors

Michał F. Kamiński¹, Cesare Hassan², Raf Bisschops³, Jürgen Pohl⁴, Maria Pellisé⁵, Evelien Dekker⁶, Ana Ignjatovic-Wilson⁷, Arthur Hoffman⁸, Gaius Longcroft-Wheaton⁹, Denis Heresbach¹⁰, Jean-Marc Dumonceau¹¹, James E. East¹²

Institutions

Institutions are listed at the end of article.

Bibliography

DOI <http://dx.doi.org/10.1055/s-0034-1365348>
Published online: 17.3.2014
Endoscopy 2014; 46: 435–449
© Georg Thieme Verlag KG
Stuttgart · New York
ISSN 0013-726X

Corresponding author

Michał F. Kamiński, MD PhD
Department of
Gastroenterological Oncology
Institute of Oncology
Roentgen Street 5
Warsaw
Poland
Fax: +48 22 546 30 57
mfkamiński@coi.waw.pl

This Guideline is an official statement of the European Society of Gastrointestinal Endoscopy (ESGE). It addresses the role of advanced endoscopic imaging for the detection and differentiation of colorectal neoplasia.

Main recommendations

1 ESGE suggests the routine use of high definition white-light endoscopy systems for detecting colorectal neoplasia in average risk populations (weak recommendation, moderate quality evidence).

2 ESGE recommends the routine use of high definition systems and pancolonic conventional or virtual (narrow band imaging [NBI], i-SCAN) chromoendoscopy in patients with known or suspected Lynch syndrome (strong recommendation, low quality evidence).

2b ESGE recommends the routine use of high definition systems and pancolonic conventional or virtual (NBI) chromoendoscopy in patients with known or suspected serrated polyposis syndrome (strong recommendation, low quality evidence).

3 ESGE recommends the routine use of 0.1% methylene blue or 0.1%–0.5% indigo carmine pancolonic chromoendoscopy with targeted biopsies for neoplasia surveillance in patients with long-standing colitis. In appropriately trained hands, in the situation of quiescent disease activity and adequate bowel preparation, nontargeted, four-quadrant biopsies can be abandoned (strong recommendation, high quality evidence).

4 ESGE suggests that virtual chromoendoscopy (NBI, FICE, i-SCAN) and conventional chromoendoscopy can be used, under strictly controlled conditions, for real-time optical diagnosis of diminutive (≤ 5 mm) colorectal polyps to replace histopathological diagnosis. The optical diagnosis has to be reported using validated scales, must be adequately photodocumented, and can be performed only by experienced endoscopists who are adequately trained and audited (weak recommendation, high quality evidence).

5 ESGE suggests the use of conventional or virtual (NBI) magnified chromoendoscopy to predict the risk of invasive cancer and deep submucosal invasion in lesions such as those with a depressed component (0-IIc according to the Paris classification) or nongranular or mixed-type laterally spreading tumors (weak recommendation, moderate quality evidence).

Conclusion

Advanced imaging techniques will need to be applied in specific patient groups in routine clinical practice and to be taught in endoscopic training programs.

Abbreviations

▼	
CAC	cap-assisted colonoscopy
CRC	colorectal cancer
EMR	endoscopic mucosal resection
ESGE	European Society of Gastrointestinal Endoscopy
FAP	familial adenomatous polyposis
FICE	Fujinon intelligent color enhancement, flexible spectral imaging enhancement
FAP	familial adenomatous polyposis
GRADE	grading of recommendations assessment, development and evaluation
HD-WLE	high definition white-light endoscopy
i-SCAN	Pentax virtual chromoendoscopy system
MAP	<i>MUTYH</i> -associated polyposis
NBI	narrow band imaging
PICO	population, intervention, comparator, outcome
PIVI	preservation and incorporation of valuable endoscopic innovations
RCT	randomized controlled trial
SD-WLE	standard definition white-light endoscopy
TER	third eye retroscope
WLE	white-light endoscopy

Introduction

Colonoscopy is widely used for colorectal cancer (CRC) detection and prevention [1, 2]. Its efficacy depends on the ability to detect colorectal neoplasia [3, 4]. In order to maximize the detection of colorectal neoplasia we may not only need to improve the examination technique and quality of bowel preparation but also to engage advanced imaging technologies such as high definition endoscopy, conventional or virtual chromoendoscopy, autofluorescence imaging (AFI) or add-on devices [5]. Some of these technologies may in addition help to characterize detected lesions and thereby guide decisions about endoscopic resection or enable real-time endoscopic diagnosis. Despite being readily available, most technologies have been little adopted into clinical practice outside academic settings [6], mostly because they are perceived as cumbersome, time-consuming and requiring special training. In our view, however, an important barrier to widespread adoption is the lack of a clear guideline on which technology is worth using in which clinical scenario.

This Guideline aims to provide endoscopists with a comprehensive review of advanced imaging techniques available for the detection and differentiation of colorectal neoplasia. We also make recommendations about the circumstances under which those techniques warrant introduction into routine clinical practice.

Methods

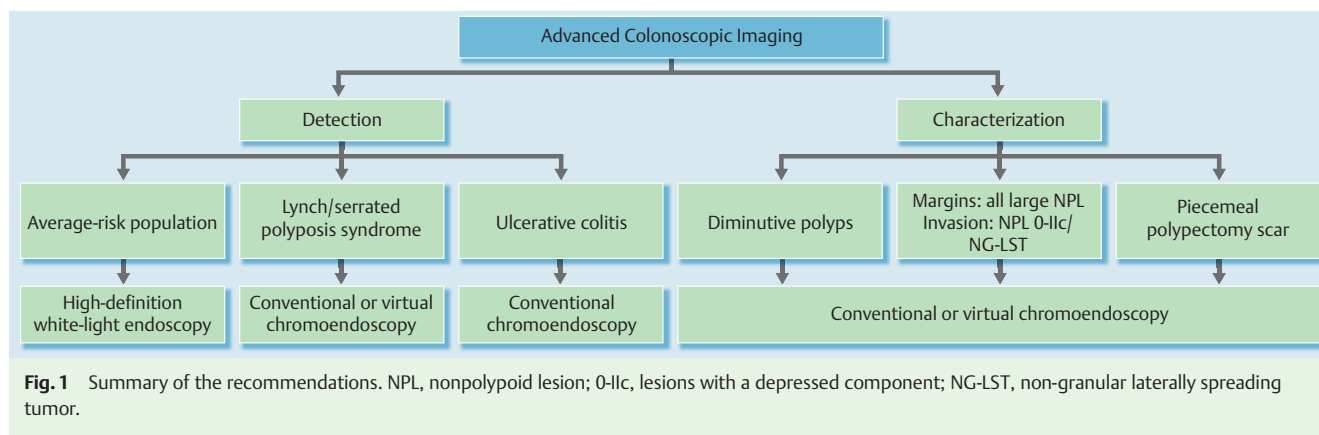
▼ The European Society of Gastrointestinal Endoscopy (ESGE) commissioned this Guideline. The guideline development process included meetings and online discussions among members of the guideline committee during December 2012 and February 2013. Subgroups were formed, each in charge of a series of clearly defined key questions (► **Appendix e1**, available online). The guideline committee chairs (C.H., J.M.D.) worked with the subgroup leaders (J.P., M.P., R.B., J.E., M.F.K.) to identify pertinent search terms that included: high definition endoscopy, chromoendos-

copy, virtual chromoendoscopy (always including additional separate searches for NBI, FICE, and i-SCAN), autofluorescence endoscopy, and add-on devices (cap-assisted colonoscopy, Third Eye Retroscope [TER]), as well as terms pertinent to specific key questions. Techniques still under development, such as confocal laser endomicroscopy, endocytoscopy, and optical coherence tomography, were not included in this Guideline. Technical aspects of advanced imaging technologies will be described in a separate technology review; they are summarized in ► **Table 1**. For ease of literature searching, key questions were formulated using PICO methodology [7].

Searches were performed on Medline (via Pubmed) and the Cochrane Central Register of Controlled Trials up to October 2012; additionally abstracts from the 2012 United European Gastroenterology Week and the 2012 Digestive Disease Week were searched. Articles were first selected by title; their relevance was then assessed by reviewing full-text articles, and publications with content that was considered irrelevant were excluded. Evidence tables were generated for each key question, summarizing the level of evidence of the available studies. For important outcomes, articles were individually assessed by using the Grading of Recommendations Assessment, Development and Evaluation (GRADE) system for grading evidence levels and recommendation strengths [8]. The GRADE system is clinically orientated as the grading of recommendations depends on the balance be-

Table 1 Summary of characteristics of advanced imaging techniques.

- High definition white-light endoscopy (HD-WLE) systems use a charge-coupled device with up to a million pixels and high definition monitors (1080 lines of vertical resolution) to provide images of higher resolution than standard definition white-light endoscopy (SD-WLE) systems.
- Conventional chromoendoscopy uses contrast dyes to enhance the visualization of colonic mucosa and to highlight surface contours. In conventional pancolonic chromoendoscopy, dye, usually indigo carmine or methylene blue, is sprayed with a catheter or is applied directly through the working channel of the endoscope in a segmental fashion onto the entire colorectal mucosa.
- Virtual chromoendoscopy refers to the use of image enhancement technologies built into the colonoscope system to alter the white-light image to enhance visualization of mucosal surface architecture and capillary pattern. All three of the key endoscope manufacturers (Olympus Medical Systems, Fujinon Endoscopy, and Pentax Medical) have introduced proprietary technologies to achieve this, with narrow band imaging (NBI), Fujinon Intelligent Color Enhancement (FICE) and i-SCAN, respectively. These systems all work differently, but have a key aim of reducing the amount of red light in the image and of narrowing the bandwidth of blue and green light.
- Autofluorescence imaging (AFI) endoscopy is based on real-time detection of natural tissue fluorescence emitted by endogenous molecules. Differences in fluorescence emission between neoplastic and non-neoplastic tissues are captured during endoscopy and visualized as magenta or green color, respectively. The device is activated by a push-button on the handle of the endoscope. AFI mode is commercially available only in the United Kingdom and Asia with EVIS Lucera Spectrum endoscopes (Olympus Medical Systems).
- Add-on devices described in this guideline (cap and third eye retroscope [TER]) were designed to increase the area of mucosal surface inspected. Endoscopic caps are transparent, single-use devices mounted on the tip of the endoscope to maintain a distance between the mucosa and the optics, and to facilitate deflection of mucosal folds. TER is a single-use, through-the-scope, retrograde viewing device, connected with a dedicated video processor to provide a retrograde view on the same monitor as the standard colonoscopy forward view.



tween benefits and risks or burden of any health intervention (Appendix e2a,b, available online). In order to answer the question on accuracy of virtual chromoendoscopy systems and AFI in differentiating between small neoplastic and non-neoplastic colorectal polyps, one of the subgroups performed a bivariate meta-analysis using a linear mixed model approach [9].

Each subgroup developed draft proposals that were presented to the entire group for general discussion during a meeting held in February 2013 (Düsseldorf, Germany). Based on evidence tables and draft proposals, key topics for further research were formulated. Further details on the methodology of ESGE guidelines have been reported elsewhere [10].

In October 2013, a draft prepared by M.F.K. and C.H. was sent to all group members. After agreement on a final version, the manuscript was submitted to the journal *Endoscopy* for publication. The journal subjected the manuscript to peer review, and the manuscript was amended to take into account the reviewers' comments. The final revised manuscript was agreed upon by all the authors.

This Guideline was issued in 2014 and will be considered for update in 2017. Any interim updates will be noted on the ESGE website: <http://www.esge.com/esge-guidelines.html>.

Recommendations and statements

Evidence statements and recommendations are stated in italics, key evidence statements and recommendations are in bold. For ease of clinical use, recommendations and statements were grouped into five categories defined by target population and/or the role of advanced imaging for detection and/or differentiation of colorectal neoplasia. Statements on the use of virtual chromoendoscopy mention in parentheses the type of technology (NBI, FICE or i-SCAN), which was proven to be effective. The summary of the recommendations is presented in Fig. 1.

Detection of colorectal neoplasia in average risk populations

The term "average risk population" is most widely used in the setting of CRC screening [11, 12]. For the purpose of this Guideline, this term applies to all patients outside the setting of colitis or hereditary syndromes. As a large number of colonoscopies are performed in average risk populations [13], even minor increases in neoplasia detection rates achieved in this population may

translate into a large effect on absolute numbers of CRC prevented. On the other hand, an advanced imaging technology should be very practical and cost-effective in order not to overload already stressed health care systems if it is to be recommended for average risk populations.

ESGE suggests the routine use of high definition white-light endoscopy systems for detecting colorectal neoplasia in average risk populations (weak recommendation, moderate quality evidence).

A meta-analysis of five studies that included 4422 average risk patients showed a 3.5% (95% confidence interval [95%CI] 0.9%–6.1%) incremental yield from high definition white-light endoscopy (HD-WLE) over standard definition white-light endoscopy (SD-WLE) for the detection of patients with at least one adenoma [14]. There were no differences between HD-WLE and SD-WLE for high risk adenomas. We postulate that the difference in the fields of view of the endoscopes that were used is unlikely to account for the increased yield observed with HD-WLE because three randomized controlled trials (RCTs), from two centers, found no significant difference in polyp detection rates between SD-WLE with 140° and 170° fields of view [15–17]. In a two-center RCT published after the meta-analysis [18], the proportion of participants in whom adenomas were detected was higher with HD-WLE compared with SD-WLE (45.7% vs. 38.6%; $P=0.166$) and the difference was significant in the proportions of patients with flat adenomas (9.5% vs. 2.4%; $P=0.003$) and with right-sided adenomas (34.0% vs. 19.0%; $P=0.001$). The cost-effectiveness of adopting HD-WLE in routine practice was not studied. High definition colonoscopes are available from all major manufacturers. *ESGE does not suggest routine use of conventional pancolonic chromoendoscopy in average risk populations, despite its proven benefit, for practical reasons (weak recommendation, high quality evidence).*

A recent Cochrane systematic review [19] analyzed five RCTs (total 1059 patients) that assessed the role of conventional chromoendoscopy in detecting colorectal lesions outside the setting of polyposis or colitis. Pancolonic chromoendoscopy significantly increased the number of patients with at least one polyp detected (odds ratio [OR] 2.22, 95%CI 1.55–3.16) and of those with at least one dysplastic lesion detected (OR 1.67, 95%CI 1.29–2.15). A limitation of the systematic review was the significant heterogeneity observed between the studies.

Since the publication of this Cochrane systematic review, four RCTs have compared HD-WLE with conventional chromoendoscopy for detecting neoplastic lesions [20–23]. Only one of them

[22] did not find that conventional chromoendoscopy detects significantly more adenomas than HD-WLE (32.7% vs. 26.9%; $P=0.47$). However this study only evaluated the detection of adenomas located in the distal colon and in the rectum. The other three studies [20, 21, 23] showed that chromoendoscopy increased the overall detection of adenomas, including flat and small adenomas. None of the studies showed an increased detection rate for advanced neoplastic lesions but none of them was sufficiently powered for this aim.

In expert hands, additional procedure duration associated with pancolonoscopic chromoendoscopy was 4–10 minutes in all studies that reported this item, i.e., a 30%–40% increase in total procedure duration [20, 23]. Additional costs associated with dyes, removal, and histopathological evaluation of additional non-neoplastic lesions and the increase in total procedure duration, coupled with the absence of evidence supporting an increased detection rate of advanced neoplasia, call against the routine use of pancolonoscopic chromoendoscopy in average risk populations.

ESGE does not recommend routine use of virtual pancolonoscopic chromoendoscopy, AFI, or add-on devices for detecting colorectal neoplasia in average risk populations (strong recommendation, high quality evidence).

Virtual chromoendoscopy

Two recent meta-analyses of RCTs compared detection [24, 25] and miss rates [25] of colonic lesions in average risk populations using white-light endoscopy (WLE) and NBI. In the meta-analysis [24], of 7 RCTs, that included a total of 2936 patients, there was no significant difference in adenoma detection rate between NBI and WLE (36% vs. 34%, $P=0.413$; relative risk [RR] 1.06, 95%CI 0.97–1.16). The other meta-analysis [25], included 9 RCTs [26–34] (3 studies published in abstracts only), and a total of 3059 patients. This meta-analysis also showed no difference between HD-NBI and HD-WLE for the detection of adenomas (OR 1.01, 95%CI 0.74–1.37), of patients with adenomas (OR 1.0, 95%CI 0.83–1.20), of flat adenomas (OR 1.26, 95%CI 0.62–2.57), nor in the miss rate of adenomas (OR 0.65, 95%CI 0.40–1.06). Two recent large, multicenter RCTs [18, 35] further corroborated the results of these meta-analyses.

Data on the use of FICE or i-SCAN for detection of colonic neoplasia during colonoscopy are scarce. Two RCTs [36, 37] did not find any difference between HD-FICE and HD-WLE concerning adenoma detection [36] or adenoma miss rate [37] in screening or surveillance colonoscopies. The single RCT that compared HD-i-SCAN with HD-WLE for screening colonoscopy showed no significant difference either in adenoma detection or in the adenoma miss rates [38].

NBI and FICE are often criticized for darkening the endoscopy image and in turn hampering the wider view of the colon [24]. Whether newer-generation, brighter systems make a difference in adenoma detection remains to be evaluated.

Autofluorescence endoscopy

Five RCTs evaluating AFI for the detection of colorectal neoplasia in average risk patients have produced conflicting results [39–43]. Details of these studies are summarized in **Appendix e3** (available online). A tandem study of AFI vs. HD-WLE [41] showed significantly lower proximal adenoma miss rates with AFI. Another RCT, from Japan [42], that allocated patients to four groups: HD-WLE alone, HD-WLE+cap-assisted colonoscopy [CAC], AFI alone, AFI+CAC, found a significantly higher number of adenomas per patient in the AFI+CAC group compared with

the HD-WLE alone group. In contrast, all three tandem RCTs that were conducted in Europe have not demonstrated differences in colorectal adenoma miss rates between AFI and HD-WLE in academic settings [40, 43] or between AFI and SD-WLE in a nonacademic setting [39].

Add-on devices

Four meta-analyses, published in 2011 and 2012, have compared the efficacy of CAC with that of regular colonoscopy [44–47]. Three of them [44–46] included between 7 and 14 RCTs for the analysis of detection of colorectal lesions; one considered available data regarding polyp detection not adequate for meta-analysis [47]. All three meta-analyses demonstrated a significantly higher polyp detection rate (by 8%–13%) but no difference in the adenoma detection rate between CAC and regular colonoscopy. Therefore, the role of CAC for the detection of colorectal neoplasia is limited.

One multicenter, tandem colonoscopy RCT compared the detection of adenomas using the “third eye” retro-scope (TER) with regular colonoscopy in an average risk population [48]. The per-protocol analysis showed that more adenomas were missed with regular colonoscopy compared with the TER (RR 1.92; 95%CI 1.07–3.44) but the difference was not statistically significant in the intention-to-treat analysis (RR 1.46, $P=0.185$). The total procedure and withdrawal times were 4 and 2 minutes longer with TER, respectively, because of device manipulation and additional polypectomies. The utility of TER in routine practice is further limited by technical difficulties with the use of the device in 5% of patients [48], impaired ability to aspirate luminal contents, relatively high cost [49], and limited availability.

Detection of colorectal neoplasia in hereditary syndromes

Advanced imaging, compared with regular colonoscopy, can potentially help in hereditary syndromes in two principal ways. First, it can assist in making a diagnosis by revealing additional lesions required to meet diagnostic criteria for sessile serrated and adenomatous polyposis syndromes [50, 51]. Second, when a hereditary CRC syndrome is diagnosed and surveillance is undertaken, advanced imaging may lead to better lesion detection thereby reducing the risk of interval cancer [52] or allowing the safe extension of surveillance intervals.

ESGE recommends the routine use of high definition pancolonoscopic chromoendoscopy in patients with known or suspected Lynch syndrome (conventional chromoendoscopy, NBI, i-SCAN) or serrated polyposis syndrome (conventional chromoendoscopy, NBI) (strong recommendation, low quality evidence).

Patients and family members with Lynch syndrome or serrated polyposis syndrome are recommended frequent, usually annual to biennial colonoscopy surveillance [53, 54] in order to minimize the risk of developing interval cancer [55, 56]. In both syndromes, precursor lesions are more likely to be nonpolypoid, located proximally, and difficult to recognize [54, 57, 58]. Four small tandem colonoscopy studies [59–62], showed higher detection rates of adenomas [59–61] or polyps [62] with conventional chromoendoscopy compared with SD-WLE or HD-WLE in patients with Lynch syndrome, at the cost of additional time (range 1.8 to 17

minutes per case) (the studies are summarized in [Appendix e4](#), available online).

The role of virtual chromoendoscopy in patients with Lynch syndrome was assessed in two prospective cohort studies [61, 63] and one RCT [64]. In the first cohort study [63] an additional pass with NBI significantly increased the proportion of patients detected with adenomas (absolute difference 15%, 95%CI 4%–25%) compared to a single pass with HD-WLE. In the other cohort study [61] the total numbers of adenomas and flat adenomas detected by a second pass with conventional chromoendoscopy were significantly higher than with a first pass using HD-NBI. In a tandem RCT [64] the miss rate of polyps was significantly lower with i-SCAN compared with HD-WLE (16% vs. 52%, respectively; $P < 0.01$).

A tandem RCT compared specifically AFI (Xillix Technologies Corporation) with HD-WLE in patients with Lynch syndrome or familial CRC [65]. The sensitivity for the detection of adenomas was significantly higher with AFI compared with HD-WLE (92% vs. 68%, $P = 0.01$). The AFI system used in this study is not widely commercially available. Although there are no studies that have assessed conventional chromoendoscopy in sessile serrated polyposis, a review that summarized serrated lesion detection in an average risk population suggested that conventional chromoendoscopy doubled the detection rate of serrated lesions, overall and in the proximal colon (no differentiation between hyperplastic and sessile serrated polyps was made) [51]. One tandem colonoscopy RCT in patients with sessile serrated polyposis [66] showed significantly lower polyp miss rates with HD-NBI compared with HD-WLE (OR 0.21; 95%CI 0.09–0.45). One pilot study showed suboptimal diagnostic accuracy of AFI in differentiation between sessile serrated polyps, hyperplastic polyps, and adenomas [67].

ESGE does not make any recommendation for the use of advanced endoscopic imaging in patients with suspected or known familial adenomatous polyposis (FAP) including attenuated and MUTYH-associated polyposis (insufficient evidence to make a recommendation).

Patients with classical FAP have hundreds of adenomas uniformly distributed in the colorectum while those with attenuated FAP and *MUTYH*-associated polyposis (MAP) have much fewer, more proximally distributed, adenomas. For surveillance, sigmoidoscopy is recommended in patients with classical FAP and colonoscopy in those with attenuated FAP or with MAP [68, 69]. In patients with classical FAP, conventional and virtual chromoendoscopy increase the detection rate of adenomas compared with HD-WLE [70]; however the clinical usefulness of these techniques is limited, because of the recommendation for proctocolectomy early in the course of the disease. In the context of attenuated FAP and of MAP, the usefulness of these techniques during surveillance is unknown.

Following proctocolectomy for FAP, small adenomas are better detected in the ileal pouch with conventional chromoendoscopy [71, 72] but the clinical significance of this finding is unclear.

Detection and differentiation of colorectal neoplasia in long-standing inflammatory bowel disease

Patients with long-standing left-sided or extensive ulcerative colitis or extensive Crohn's colitis are recommended to have intensive colonoscopic surveillance because of an increased risk of CRC compared with the average risk population [53, 73]. Advanced

imaging may be of benefit by: (i) increasing the detection of dysplasia [74]; (ii) improving the differentiation of lesions (colitis associated neoplasia, sporadic neoplasia [75, 76], and non-neoplastic lesions); and (iii) reducing the number of unnecessary biopsies.

ESGE recommends the routine use of 0.1% methylene blue or 0.1%–0.5% indigo carmine pancolonoscopic chromoendoscopy with targeted biopsies for neoplasia surveillance in patients with long-standing colitis. In appropriately trained hands, in the situation of quiescent disease activity and adequate bowel preparation, nontargeted four-quadrant biopsies can be abandoned (strong recommendation, high-quality evidence).

Two sufficiently powered RCTs compared the diagnostic yield of conventional chromoendoscopy and SD-WLE [77, 78]. Additionally, one high quality meta-analysis [79] including these two RCTs and four cohort studies confirmed the overall findings in 1277 patients from a well-defined target population (disease duration > 8 years). In the meta-analysis the pooled incremental yield of conventional chromoendoscopy with random biopsies over SD-WLE with random biopsies for the detection of patients with neoplasia was 7% (95%CI 3.2%–11.3%). Moreover, the difference in proportion of lesions detected by targeted biopsies only was 44% (95%CI 28.6%–59.1%) in favor of conventional chromoendoscopy. Two prospective cohort studies [80, 81] published after the meta-analysis further corroborated the results. Overall, in 8 prospective studies comparing conventional chromoendoscopy with SD-WLE, the former consistently increased the proportion of patients found with dysplasia with a factor 2.08–3.26 [77–81].

Although in all the abovementioned studies [77–81] random four-quadrant biopsies were taken as a back-up method in conjunction with chromoendoscopy-targeted biopsies, the diagnostic yield of those back-up biopsies was rather limited. The pooled sensitivity for the detection of neoplasia with chromoendoscopy-targeted biopsies only was 86% (range 71%–100%) for all studies that reported this data and 95% (range 87%–100%) after exclusion of one study [82] in which targeted rather than pancolonoscopic chromoendoscopy was used ([Appendix e5](#), available online; [77, 78, 80–82, 83, 84, 85]). The median number of targeted biopsies sampled per procedure was 1.3 (range 0.28–14.2) and the median number of targeted plus random biopsies per procedure was 34.3 (range 7.0–42.2).

The number of biopsies needed during conventional chromoendoscopy surveillance of long-standing colitis can therefore be significantly reduced if only targeted biopsies are taken. The case for abandoning random biopsies is further supported by evidence of poor adherence to endoscopic protocols for random biopsies in clinical practice [86]. There is however no evidence to show what the process of pancolonoscopic chromoendoscopy training and abandoning random biopsies should look like. It has been suggested during expert discussion at the Disease Digestive Week 2009 (T.A. Ullman and R. Kiesslich) that the following logical steps should be undertaken: (i) chromoendoscopy training with an expert on at least 30 colonoscopies; (ii) chromoendoscopy with targeted and random biopsies; (iii) chromoendoscopy with random biopsies in special situations only (multiple post-inflammatory polyps, neoplasia on previous colonoscopy, etc); and (iv) chromoendoscopy with targeted biopsies only.

In studies summarized in the meta-analysis cited above [79], the duration of surveillance colonoscopy in long-standing colitis was

longer with pancolonoscopic chromoendoscopy plus random biopsies compared with SD-WLE with random biopsies, by an average 11 minutes (95%CI 10 min 15 s to 11 min 43 s). It is likely, however, that the duration of pancolonoscopic chromoendoscopy with only targeted biopsies is comparable to or shorter than that of WLE with random biopsies [84, 85].

In all prospective studies [77–81] 0.1% methylene blue or 0.1–0.5% indigo carmine solutions were used for chromoendoscopy, with no evidence for difference in their efficacy. Some concern was raised by a report on oxidative DNA damage in Barrett's epithelium caused by methylene blue in combination with photosensitization by WLE [87], but there is no clinical evidence indicating an increased risk in patients with long-standing colitis.

Limitations of conventional chromoendoscopy in the context of long-standing colitis surveillance needs to be mentioned. There is no proof that better detection of neoplasia by conventional chromoendoscopy translates into reduced CRC mortality or decreased risk of interval CRC. Cost-effectiveness is also unclear for chromoendoscopy compared to WLE plus random biopsies, although it may be cheaper when combined with risk stratification thereby entailing fewer colonoscopies and fewer histological samples [88]. It is unknown whether there would be any benefits of conventional chromoendoscopy over WLE with newer-generation HD-WLE colonoscopes. Several prerequisites are listed in the SURFACE guidelines [89], such as quiescent disease and excellent bowel preparation, which must be met in the performance of pancolonoscopic chromoendoscopy surveillance. Nevertheless the use of pancolonoscopic chromoendoscopy with only targeted biopsies for dysplasia detection in colitis is now strongly endorsed by the British Society of Gastroenterology [90], and the European Crohn's and Colitis Organization [91].

ESGE found insufficient evidence to recommend for or against the use of virtual chromoendoscopy or autofluorescence imaging (AFI) for the detection of colorectal neoplasia in inflammatory bowel disease (insufficient evidence to make a recommendation).

Three RCTs compared virtual chromoendoscopy (NBI in all cases) with WLE for the detection of neoplasia in long-standing inflammatory bowel disease [92–94]. Regardless of generation of NBI and the level of definition of colonoscopes used, virtual chromoendoscopy did not significantly increase the detection rate of neoplastic lesions compared with WLE [92–94]. However, in all three RCTs, virtual chromoendoscopy with targeted biopsies alone yielded neoplasia detection rates comparable to WLE with targeted and nontargeted four-quadrant biopsies [92–94]. Mean number of biopsies per patient was 0.5 to 3.5 in NBI with targeted biopsies only and 24.6 to 38.3 in WLE with targeted and random quadrant biopsies [92, 94].

Two RCTs compared an HD-NBI system with high definition conventional chromoendoscopy, both without nontargeted biopsies, for the detection of neoplasia in long-standing inflammatory bowel disease [95, 96]. The first study was a single-center, crossover RCT aimed at comparing neoplasia miss rates with HD-NBI and high definition conventional chromoendoscopy [95]. The miss rate of neoplastic lesions was considerably higher with HD-NBI compared with high-definition conventional chromoendoscopy (31.8% and 13.6%, respectively) but the study was not powered enough to test the observed difference for statistical significance. The second study was a multicenter, parallel group RCT aimed at comparing neoplasia detection rates with HD-NBI and high definition conventional chromoendoscopy [96]. Preliminary results (108 of 134 planned patients have been included) showed similar neoplasia detection rates for NBI and conventional chro-

moendoscopy, per lesion (24.0% and 17.2%, respectively; $P=0.385$) and per patient (18.5% and 16.7%, respectively). Median withdrawal time was significantly shorter in the NBI group compared to the chromoendoscopy group (21 vs. 27 minutes, respectively; $P=0.003$).

There were only two studies, of which one was an RCT, comparing HD-WLE with AFI for the detection of colorectal neoplasia in inflammatory bowel disease [94, 97]. A pilot study [97] showed that protruding lesions with a low autofluorescence signal were significantly more likely to be neoplastic than lesions with a high autofluorescence signal (45.0% vs. 13.3%, respectively, $P=0.043$). In the RCT, the miss rate for neoplastic lesions was statistically significantly lower with AFI compared with HD-WLE (0% vs. 50%, $P=0.036$). It should be noted that inadequate bowel preparation and active inflammation interrupt tissue autofluorescence, resulting in discoloration on AFI and resembling neoplasia [97]. Further studies including comparison with conventional chromoendoscopy are needed.

ESGE recommends taking biopsies from flat mucosa surrounding neoplastic lesions and taking biopsies from or resecting all suspicious lesions identified at neoplasia surveillance in long-standing colitis, because there is no evidence that nonmagnified conventional or virtual chromoendoscopy can reliably differentiate between colitis-associated and sporadic neoplasia or between neoplastic and non-neoplastic lesions (strong recommendation, low to moderate quality evidence).

Neoplastic vs. non-neoplastic lesions

A modified pit pattern classification has been used in three conventional chromoendoscopy studies to differentiate between neoplastic and non-neoplastic lesions in long-standing inflammatory bowel disease [77, 80, 82]. The surface staining pattern allowed differentiation between neoplastic and non-neoplastic lesions with high sensitivity and specificity (93%–100% and 88%–97%, respectively) [77, 80, 82]. However, in the reported studies magnifying endoscopes, which are not widely available, were used for lesion characterization and total procedure times were on average 9–11 minutes longer. No studies report on differentiation between neoplastic and non-neoplastic lesions in inflammatory bowel disease using nonmagnifying colonoscopes with conventional chromoendoscopy.

Four studies evaluated the role of non-magnified NBI in differentiating neoplastic and non-neoplastic lesions in patients with long-standing colitis [94, 98–100]. One case report [100] and one pilot study [99] showed that a tortuous pit pattern and a high vascular pattern intensity may help to distinguish neoplastic and non-neoplastic lesions in long-standing colitis. In two small RCTs [94, 98] the sensitivity and specificity of NBI in predicting histology were unsatisfactory. In one of these RCTs [94] combining AFI with NBI increased sensitivity for predicting histology from 75% to 100% without a major drop in specificity. No other virtual chromoendoscopy systems were assessed for differentiation of lesions in the setting of colitis.

Colitis-associated vs. sporadic neoplasia

Current guidelines suggest taking biopsies from the flat mucosa surrounding neoplastic lesions in long-standing colitis, because differentiation between colitis-associated and sporadic neoplasia is crucial in determining their optimal management [73, 90]. Although it has been suggested that conventional chromoendoscopy cannot distinguish these two entities because of a similar staining pattern [89], it has recently been shown that magnifying

conventional chromoendoscopy combined with NBI can be useful for this purpose if the borders of the circumscribed lesion are thoroughly assessed [75]. This finding has to be confirmed by larger and more robust studies.

Differentiation between neoplastic and non-neoplastic diminutive colorectal polyps

It is current practice to resect all colorectal polyps and to send them for histological analysis. This is expensive and generates a large burden of work for histopathology departments. In considering diminutive polyps (≤ 5 mm in size), which represent approximately 60% of all polyps detected at primary screening colonoscopy [101, 102], the main goal of histological examination is to differentiate between neoplastic and non-neoplastic lesions in order to determine the need and timing for surveillance colonoscopy. Techniques for optical diagnosis using advanced imaging have been developed which have the potential to supplement or replace formal histological diagnosis with in vivo optical diagnosis [103–105]. A “resect and discard” policy has been proposed which suggests making a real-time optical diagnosis of diminutive colorectal polyps using advanced imaging, photodocumenting them, and resecting and discarding them without histological assessment [103]. This could not only reduce costs for histological assessment but also allow an immediate recommendation regarding the interval to the next colonoscopy [106]. It was further proposed to photodocument and leave in situ diminutive polyps in the rectosigmoid region considered to be non-neoplastic at optical diagnosis [106]. A recent statement from the American Society for Gastrointestinal Endoscopy [106] (Preservation and Incorporation of Valuable endoscopic Innovations [PIVI] statement) has attempted to set standards against which a technology should be assessed in order to be deemed suitable for applying a policy of resect and discard ($\geq 90\%$ agreement in assignment of post-polypectomy surveillance intervals when compared with decisions based on pathology assessment) or a policy of leaving suspected non-neoplastic polyps in place ($\geq 90\%$ negative predictive value, when used with high confidence).

ESGE suggests that virtual chromoendoscopy (NBI, FICE, i-SCAN) and conventional chromoendoscopy can be used, under strictly controlled conditions, for real-time optical diagnosis of diminutive (≤ 5 mm) colorectal polyps to replace histopathological diagnosis. The optical diagnosis has to be reported using validated scales, must be adequately photodocumented, and can be performed only by experienced endoscopists who are adequately trained and audited (weak recommendation, high quality evidence).

Major concerns regarding the use of optical diagnosis techniques are that advanced pathology (i.e. high grade dysplasia, tubulovillous or villous morphology) and cancers might be missed, leading to setting of inappropriate surveillance intervals or suboptimal treatment. However, the risk estimates for advanced pathology are low for polyps ≤ 5 mm in size (ranging from 0.1% to 26%, with most estimates tending towards the lower end of this range; **Appendix e6**, available online; [102, 105, 107–132]). Moreover, data are limited on the importance of advanced pathology in small and diminutive polyps in terms of the future risk of advanced pathology or cancer. This is further confounded by the poor agreement between even expert pathologists for the diagnosis of villosity or high grade dysplasia, with 10-fold variation

in rates [133–135]. Given this variability, British guidelines have chosen to ignore these characteristics and use size only as a criterion, and United European guidelines have chosen to add them as accessory criteria, whereas the ESGE and American guidelines use these features to determine surveillance intervals [90, 136–138]. A second concern is the rate of carcinoma in diminutive polyps which is very low but not negligible (the risk estimate for lesions ≤ 5 mm ranges from 0% to 0.6%, again with most estimates at the lower end of the range; see the summary of evidence in **Appendix e6**). Although it is unknown whether diminutive cancer polyps harbor the same characteristics as larger cancer polyps at endoscopic examination, it is generally recommended that optical biopsy be avoided in suspicious lesions (e.g. depressed lesions, Paris classification 0-IIc) [139], which might further reduce the risk of missing a cancer.

A meta-analysis that included 56 studies [9] showed that the overall sensitivity and specificity of NBI for differentiation between neoplastic and non-neoplastic colorectal polyps were 91.0% (95%CI 88.6%–93.0%) and 85.6% (95%CI 81.3%–89.0%), respectively. In a subset of real-time assessment studies, the negative predictive value (NPV) was 82.5% (95%CI 75.4%–87.9%). For FICE, this meta-analysis included 14 studies; the corresponding overall sensitivity, specificity and NPV were 91.8% (95%CI 87.1%–94.9%), 83.5% (95%CI 77.2%–88.3%), and 83.7% (95%CI 77.5%–88.4%). For i-SCAN this meta-analysis included 10 studies; the corresponding overall sensitivity, specificity and NPV were 89.3% (95%CI 83.3%–93.3%), 88.2% (95%CI 80.3%–93.2%), and 86.5% (95%CI 78.0%–92.1%). For AFI this meta-analysis included 11 studies; the corresponding overall sensitivity, specificity and NPV were 86.7% (95%CI 79.5%–91.6%), 65.9% (95%CI 50.9%–78.2%), and 81.5% (95%CI 54.0%–94.3%). There were no significant differences between real-time versus post-procedure studies [9]. The effect of high definition on diagnostic performance of real-time assessments remains uncertain [9, 140]. The abovementioned results for NBI are in accordance with those reported in another recent meta-analysis [141]. The diagnostic performance of optical diagnosis for NBI, FICE and i-SCAN (not AFI) would be acceptable for clinical use according to PIVI requirements and it should be possible to estimate surveillance intervals with NBI, FICE or i-SCAN with at least 90% accuracy [106]. Although NPVs did not quite meet the 90% standard set in the PIVI, most studies looked at polyps throughout the colon and not just rectosigmoid diminutive lesions. Conventional chromoendoscopy shows similar accuracy in differentiating between neoplastic and non-neoplastic polyps [36, 142], but because of inconvenience and costs associated with the use of dyes it is unlikely to be adopted in routine clinical practice.

Although there is now significant evidence for using virtual chromoendoscopy-based optical diagnosis, most data come from enthusiasts or experts and may not represent the actual performance by community gastroenterologists [143–145]. Indeed available data suggest a significant interobserver variability (**Appendix e7**, available online; [104, 121, 122, 124, 146–152]) and learning curve [153, 154], which can to some extent be rapidly surmounted with training [155–158], but achievement of the performance reported by experts may take longer [143]. No universal training system for differentiation between neoplastic and non-neoplastic colorectal polyps has yet been established, but all of three computer-based training modules using still photographs [155, 156, 158] achieved significant improvement in accuracy, and one using videos resulted in improvements both in accuracy and in the number of “high confidence” assessments

[157]. With the use of validated scales, such as the NBI International Colorectal Endoscopic (NICE) classification [159], diagnostic accuracy of in vivo optical diagnosis will likely improve, and interobserver variability decrease. However, it has to be emphasized that new or updated scales should incorporate sessile serrated polyps/adenomas in their classification systems [160].

Computer algorithms that analyze the polyp image may be able to support clinician decision making at optical biopsy and help community-based gastroenterologists to meet the required standards. Four studies reported on the diagnostic performance of computer-aided classification systems for NBI images, showing 82%–98% sensitivity and 61%–98% specificity for differentiation between neoplastic and non-neoplastic colorectal polyps [161–164]. Computer-aided diagnostic performance appears to be improving with two recent large NBI studies reporting diagnostic accuracy equivalent to expert readers [163, 164]; however magnifying endoscopes were used in these studies, making use in the community challenging.

There are currently no data to suggest what kind of documentation is needed for the resect and discard policy. The PIVI document [106] stated that, as an endoscopic photograph rather than a histology slide becomes the record of a small polyp, photographs must be stored to be used not only as evidence of adenoma detection but also of accuracy of optical diagnosis. This poses significant challenges at present, especially with regard to recording in high definition and the available disk space on servers in endoscopy units.

There is moderate quality evidence from several large and well conducted studies that in vivo optical diagnosis using NBI or FICE would be a cost-effective alternative to histology especially for diminutive polyps [103, 165–167] (► **Appendix e8**, available online). No studies to date have looked at i-SCAN for this purpose, although it shows a similar degree of accuracy as NBI and hence the findings on cost-effectiveness would be transferable. Two British prospective cohort studies [103, 166] and one American retrospective multicenter cohort study [165] showed a simple reduction in costs of histopathology of €62–€210 per colonoscopy associated with the use of a resect and discard policy. A Markov modelling study showed that a resect and discard policy applied to a US screening population [167] would allow for annual undiscounted savings of \$33 million/year (\$25 [€20]/person) with negligible impact on surveillance intervals or screening efficacy. Concerns associated with the data used for model analysis include: (i) the use of US and UK models of screening for CRC, which may not be simply transferred to the various screening programs in use in Europe; (ii) the use of assumptions derived from studies performed by experts; and (iii) the exclusion of costs associated with implementation of the resect and discard policy (training for and photodocumentation of real-time diagnosis).

Advanced endoscopic imaging in the treatment of neoplasia

Advanced endoscopic imaging techniques can be particularly suited for optimizing the endoscopic resection of large sessile or nonpolypoid colorectal lesions and for post-resection surveillance. Such lesions scheduled for endoscopic resection require adequate delineation of margins, prediction of the risk of invasive cancer and deep submucosal invasion, and thorough post-resection surveillance for residual neoplasia. These lesions should be removed by level 4 competent endoscopists [168], who usually

work at tertiary referral centers, where advanced endoscopic imaging is often readily available.

ESGE suggests the use of conventional or virtual (NBI) magnified chromoendoscopy to predict the risk of invasive cancer and deep submucosal invasion in lesions such as those with a depressed component (0-IIc according to the Paris classification) or nongranular or mixed-type laterally spreading tumors (weak recommendation, moderate quality evidence).

Superficially invasive submucosal CRCs are amenable to endoscopic resection under strictly controlled criteria [169, 170]. Advanced endoscopic imaging may help to differentiate between noninvasive lesions and superficially invasive submucosal cancers so that the appropriate endoscopic removal technique can be used and the resection site tattooed. In addition, advanced imaging may help to predict the risk of deep submucosal cancer which is associated with increased risk of lymph node metastases and perforation and bleeding, and requires surgical treatment [169–171].

Risk of submucosal invasion

Certain mucosal and vascular patterns of colorectal lesions have been associated with the risk of submucosal (or deeper) cancer being found at histological examination [172, 173]. At magnifying chromoendoscopy, a Kudo V pit pattern predicted a substantially higher risk of invasive cancer compared with non-V pit patterns (II–IV). In detail, pit pattern V has been associated with a risk of deep submucosal cancer greater than 40%, and it has been further divided in two subtypes, namely Vi (irregular) and Vn (nonstructured), which have been associated with a 20%–30% and >90% risk of submucosal invasion, respectively [172, 174–176]. The sensitivity of pit pattern V for the diagnosis of submucosal (or deeper) cancer was 85% in a large Japanese series and 79% in a European cohort study [176, 177]. A few studies also addressed whether the classification of the vascular pattern or combined vascular-surface pattern of the lesion at magnifying virtual chromoendoscopy was able to predict the risk of underlying malignancy. In Japanese series, an irregular or a sparse vascular pattern on magnified NBI have been associated, with a 50% or >90% risk, respectively, of submucosal (or deeper) cancer, such risk being marginal in those lesions with other vascular patterns [173, 178, 179].

Depth of submucosal invasion

Several endoscopic studies addressed whether mucosal or vascular patterns at magnifying chromoendoscopy are able to predict the level of submucosal invasion. A Japanese series showed that pit pattern Vn was highly predictive of deep submucosal invasion (100%), whilst such a risk broadly ranged between 17%–85% in those with pit pattern Vi [176]. For this reason, it has been proposed to further subclassify pit pattern Vi, according to the severity of the irregularity in the mucosal pattern. In particular, the risk of deep submucosal invasion has been shown to be very high in those with more severe irregularity [175, 180, 181].

Factors other than pit pattern have also been considered as predictors of deep submucosal invasion at magnifying colonoscopy. Two studies showed that some morphological characteristics at magnifying colonoscopy—including fold convergence, an expansive appearance, an irregular surface contour, a demarcated depressed area, or a >1 cm nodule—predicted deep submucosal invasion with a higher sensitivity and equal specificity compared

with the nonlifting sign [182, 183]. In a recent large prospective analysis, combined mucosal and morphological invasive patterns at magnifying conventional chromoendoscopy have been confirmed to be highly predictive of deep submucosal invasion with a 98.8% overall accuracy [184]. Vascular pattern at magnified NBI has also been associated with the depth of cancer invasion. In particular, an irregular/sparse or severely irregular pattern has been shown to be predictive of deep submucosal invasion with sensitivity and specificity of 83%–100% and 72%–100%, respectively [173, 176].

The predictions of submucosal invasion and depth of invasion at magnified virtual or conventional chromoendoscopy have however never been compared with routine predictions made by endoscopists at nonmagnified WLE, which means that we do not know the added value of advanced imaging over routine practice. Moreover, magnifying colonoscopes are not yet widely available in Europe so the applicability of assessments based on magnified views may be limited.

Recently, an expanded NICE classification for the characterization of deep submucosal cancer has been proposed [185]. Its advantages are the use of nonmagnified views and objective criteria for assessing deep submucosal invasion. On the other hand the overall accuracy of the expanded NICE classification for diagnosing submucosal invasion was relatively low (70% and 50% high confidence predictions, with 84% and 90% accuracy for experts and trained novices, respectively), and the scale was validated using only still images. The ability to predict the risk of submucosal (or deeper) cancer using different virtual chromoendoscopy systems was not assessed.

Irrespective of the accuracy of magnified or nonmagnified virtual or conventional chromoendoscopy in predicting potential submucosal invasion, it is questionable whether such techniques should be applied to all lesions. Their clinical impact would necessarily depend also on the expected prevalence of submucosal (or deeper) invasion. In large Japanese, US, and European series, the risk of submucosal (or deeper) cancer appeared to be low (<2%) in 0-IIa or 0-IIb lesions, as well as in homogeneous granular-type laterally spreading tumors (LSTs) [176, 186–192]. Such a risk appeared to be substantially higher (up to 36%) for nonpolypoid lesions with a depressed component (0-IIc) and nongranular or mixed LSTs [176, 186–192]. The addition of mucosal and vascular pattern stratification, using virtual or conventional chromoendoscopy, to the morphological classification of nonpolypoid lesions and presence or not of the nonlifting sign may be the most informative way to guide decisions on whether to undertake endoscopic or surgical resection.

ESGE recommends the use of virtual or conventional chromoendoscopy to define the margins of large nonpolypoid or otherwise indistinct lesions before or during endoscopic resection (strong recommendation, very low quality evidence).

Incomplete resection has been suggested to contribute significantly to the risk of interval or post-polypectomy CRC [193, 194]. Recently it has been shown that incomplete resection of 5–20 mm neoplastic polyps occurs in approximately 10% of cases and that this risk significantly increases with polyp size and sessile serrated histology [195]. Therefore, advanced endoscopic imaging may be particularly useful to assist with endoscopic resection of large nonpolypoid or otherwise indistinct lesions. Despite the fact that many centers commonly use conventional chromoendoscopy to delineate large sessile or nonpolypoid colorectal lesions prior to endoscopic resection (either surface staining [196, 197] or stain solution injection [198, 199]) the evidence

Table 2 Key topics for further research.

1. What are the neoplasia detection rates of conventional chromoendoscopy, virtual chromoendoscopy, and autofluorescence imaging compared with high definition white-light endoscopy (HD-WLE) in patients with Lynch syndrome (tested in a multicenter, parallel group randomized controlled trial [RCT])? Does advanced imaging reduce interval colorectal cancer (CRC) rates or allow extension of colonoscopy surveillance intervals?
2. What is the role of conventional or virtual chromoendoscopy in the diagnosis and surveillance of patients with sessile serrated polyposis?
3. What is the role of advanced imaging in the diagnosis of attenuated familial adenomatous polyposis (FAP) and *MUTYH*-associated polyposis in patients with multiple adenomas?
4. What are the neoplasia detection rates of newer-generation narrow band imaging (NBI) and other virtual chromoendoscopy systems in long-standing inflammatory bowel disease?
5. Does conventional chromoendoscopy allow the lengthening of colonoscopy surveillance intervals in long-standing colitis or reduce interval cancer rates? How should endoscopists be trained in conventional chromoendoscopy, and at what point on the learning curve can we abandon random, four-quadrant biopsies?
6. What are the neoplasia detection rates of conventional chromoendoscopy compared with HD-WLE, autofluorescence imaging, and virtual chromoendoscopy in long-standing inflammatory bowel disease?
7. What is the role of advanced imaging in differentiation between colitis-associated neoplasia and sporadic neoplasia in long-standing inflammatory bowel disease?
8. What is the role of nonmagnified advanced imaging in differentiation between neoplastic and non-neoplastic lesions in long-standing inflammatory bowel disease?
9. What is the diagnostic accuracy of virtual chromoendoscopy for differentiation of diminutive rectosigmoid polyps? What is the performance of community endoscopists when using validated classification scales?
10. What is the diagnostic accuracy of virtual chromoendoscopy for differentiation of diminutive sessile serrated lesions from hyperplastic polyps? How should sessile serrated polyps be incorporated into new or updated classification systems?
11. What is the performance of virtual chromoendoscopy for differentiating between neoplastic and non-neoplastic diminutive polyps by community gastroenterologists using validated scales? What is the role of computer-aided diagnosis?
12. What is the diagnostic accuracy of advanced imaging techniques for detection of residual neoplasia at endoscopic mucosal resection (EMR) or piecemeal polypectomy scars?
13. What is the diagnostic accuracy of advanced imaging techniques for delineation of colorectal neoplasia before endoscopic removal?

that this results in more radical resection is very weak. One large prospective, single-center study assessed the usefulness of high magnification conventional chromoendoscopy in predicting completeness of endoscopic mucosal resection (EMR) based on pit pattern analysis of resection margins [196]. High magnification conventional chromoendoscopy yielded 80% sensitivity for predicting remnant neoplastic tissue at resection margins. In another study, high magnification endoscopy alone was used to predict remnant neoplastic tissue at piecemeal polypectomy sites, with 98% sensitivity and 90% specificity [200]. This approach, however, has never been tested against WLE assessment, and requires high magnification endoscopes. The usefulness of submucosal injection using methylene blue solution has been formally assessed only in one pilot study of 25 polyps and using subjective criteria [201].

No studies were found that compared focal, surface application of dyes or virtual chromoendoscopy with WLE for delineation of colorectal neoplasia before endoscopic removal. Despite the lack of evidence, conventional or virtual chromoendoscopy can be advised for delineation of colorectal lesions because it offers potential benefit at relatively low time and cost.

ESGE recommends the use of virtual or conventional chromoendoscopy in addition to white light endoscopy for the detection of residual neoplasia at a piecemeal polypectomy scar site (strong recommendation, low quality evidence).

Large sessile or nonpolypoid colon polyps are often removed in a piecemeal fashion which is associated with a mean recurrence rate of 25% [202]. Professional societies recommend endoscopic follow up at 2 to 6 months after piecemeal resection of colorectal polyps to check for residual neoplasia [136, 137]. HD-WLE alone identifies 69% to 83% of recurrences revealed by targeted and random biopsies [202, 203]. One study on high definition virtual chromoendoscopy and one study on high magnification conventional chromoendoscopy showed that advanced imaging identified neoplastic lesions that were not detected using SD-WLE or HD-WLE alone [204, 205]. One prospective study showed that high magnification conventional chromoendoscopy without random biopsies detected all 8 recurrences evidenced over 2 years of endoscopic follow-up in patients who underwent EMR of LSTs [206]. However a recent study [203] showed poor sensitivity and specificity of high definition virtual chromoendoscopy (72% and 78%, respectively) in predicting neoplastic histology of EMR scars as compared with conventional histopathology. Further studies are needed to establish whether the diagnostic accuracies of conventional or virtual chromoendoscopy are high enough to justify abandoning biopsy of macroscopically normal EMR or piecemeal polypectomy scars.

Key topics for further research

Despite a thorough literature search some of the key questions remained unanswered and other research questions were formulated as a consequence of the analysis of the available evidence. **Table 2** summarizes key topics for further research in advanced imaging for the detection and differentiation of colonic neoplasia.

Use of the guideline

Caution: In addition to the legal disclaimer applicable to all ESGE guidelines [10], it is mentioned that methylene blue is contraindicated in individuals with glucose-6-phosphate dehydrogenase deficiency.

ESGE guidelines represent a consensus of best practice based on the available evidence at the time of preparation. They may not apply in all situations and should be interpreted in the light of specific clinical situations and resource availability. Further controlled clinical studies may be needed to clarify aspects of these statements, and revision may be necessary as new data appear. Clinical consideration may justify a course of action at variance to these recommendations. ESGE guidelines are intended to be an educational device to provide information that may assist endoscopists in providing care to patients. They are not rules and should not be construed as establishing a legal standard of care or as encouraging, advocating, requiring, or discouraging any particular treatment.

Competing interests: R. Bisschops, speaker (Pentax Europe, Fujifilm and Olympus); E. Dekker, research grant and equipment on loan (Olympus), travel grant (Norgine and Tillots); J. East, advisory board (Cosmo Pharmaceuticals), speaker (Abbott Labs/Abbvie), equipment on loan (Olympus and Pentax); M. Kaminski, speaker (Olympus, Ipsen Pharmaceuticals).

Institutions

- ¹ Department of Gastroenterology and Hepatology, Medical Centre for Postgraduate Education, Maria Skłodowska-Curie Memorial Cancer Centre and Institute of Oncology, Warsaw, Poland
- ² Digestive Endoscopy Unit, Nuovo Regina Margherita Hospital, Rome, Italy
- ³ Department of Gastroenterology, University Hospital Leuven, Leuven, Belgium
- ⁴ Department of Gastroenterology and Interventional Endoscopy, Klinikum im Friedrichshain, Berlin, Germany
- ⁵ Department of Gastroenterology, Institut de Maladies Digestives i Metabòliques, Hospital Clinic, Barcelona, Spain
- ⁶ Department of Gastroenterology and Hepatology, Academic Medical Centre, Amsterdam, The Netherlands
- ⁷ Wolfson Unit for Endoscopy, St Mark's Hospital, Imperial College London, UK
- ⁸ Medizinische Klinik, St. Mary Hospital, Frankfurt, Germany
- ⁹ Department of Gastroenterology, Queen Alexandra Hospital, Portsmouth Hospitals NHS Trust, Portsmouth, United Kingdom
- ¹⁰ Department of Gastroenterology, University Hospital, CHU Rennes, France
- ¹¹ Gedyt Endoscopy Center, Buenos Aires, Argentina
- ¹² Translational Gastroenterology Unit, John Radcliffe Hospital, Oxford University, Oxford, United Kingdom.

References

- 1 Stock C, Brenner H. Utilization of lower gastrointestinal endoscopy and fecal occult blood test in 11 European countries: evidence from the Survey of Health, Aging and Retirement in Europe (SHARE). *Endoscopy* 2010; 42: 546–556
- 2 Sonnenberg A, Amorosi SL, Lacey MJ et al. Patterns of endoscopy in the United States: analysis of data from the Centers for Medicare and Medicaid Services and the National Endoscopic Database. *Gastrointest Endosc* 2008; 67: 489–496
- 3 Kaminski MF, Regula J, Kraszewska E et al. Quality indicators for colonoscopy and the risk of interval cancer. *N Engl J Med* 2010; 362: 1795–1803
- 4 Meester RG, Corley DA, Doubeni CA et al. Impact of variation in screening colonoscopy quality on the prevention of colorectal cancer deaths. A modelling study. *Gastroenterology* 2013; 144: 190
- 5 Rex DK. Maximizing detection of adenomas and cancers during colonoscopy. *Am J Gastroenterol* 2006; 101: 2866–2877
- 6 Spiegel BM, Ho W, Esrailian E et al. Controversies in ulcerative colitis: a survey comparing decision making of experts versus community gastroenterologists. *Clin Gastroenterol Hepatol* 2009; 7: 168–174, 174 e1
- 7 Richardson WWM, Nishikawa J, Hayward R. The well-built clinical question: A key to evidence-based decisions. *ACP Journal Club* 1995; 123: A12–A13
- 8 Atkins D, Best D, Briss PA et al. Grading quality of evidence and strength of recommendations. *BMJ* 2004; 328: 1490

- 9 Wanders LK, East JE, Uitentuis SE et al. Diagnostic performance of narrowed spectrum endoscopy, autofluorescence imaging, and confocal laser endomicroscopy for optical diagnosis of colonic polyps: a meta-analysis. *Lancet Oncol* 2013; 14: 1337–1347 [Epub 2013 Nov 13]
- 10 Dumonceau JM, Hassan C, Riphaus A et al. European Society of Gastrointestinal Endoscopy (ESGE) Guideline Development Policy. *Endoscopy* 2012; 44: 626–629
- 11 Winawer S, Fletcher R, Rex D et al. Colorectal cancer screening and surveillance: clinical guidelines and rationale—Update based on new evidence. *Gastroenterology* 2003; 124: 544–560
- 12 von Karsa L, Patnick J. European Colorectal Cancer Screening Guidelines Working Group. et al. European guidelines for quality assurance in colorectal cancer screening and diagnosis: overview and introduction to the full supplement publication. *Endoscopy* 2013; 45: 51–59
- 13 Lieberman DA, Holub J, Eisen G et al. Utilization of colonoscopy in the United States: results from a national consortium. *Gastrointest Endosc* 2005; 62: 875–883
- 14 Subramanian V, Mannath J, Hawkey CJ et al. High definition colonoscopy vs. standard video endoscopy for the detection of colonic polyps: a meta-analysis. *Endoscopy* 2011; 43: 499–505
- 15 Deenadayalu VP, Chadalawada V, Rex DK. 170 degrees wide-angle colonoscope: effect on efficiency and miss rates. *Am J Gastroenterol* 2004; 99: 2138–2142
- 16 Fatima H, Rex DK, Rothstein R et al. Cecal insertion and withdrawal times with wide-angle versus standard colonoscopes: a randomized controlled trial. *Clin Gastroenterol Hepatol* 2008; 6: 109–114
- 17 Rex DK, Chadalawada V, Helper DJ. Wide angle colonoscopy with a prototype instrument: impact on miss rates and efficiency as determined by back-to-back colonoscopies. *Am J Gastroenterol* 2003; 98: 2000–2005
- 18 Rastogi A, Early DS, Gupta N et al. Randomized, controlled trial of standard-definition white-light, high-definition white-light, and narrow-band imaging colonoscopy for the detection of colon polyps and prediction of polyp histology. *Gastrointest Endosc* 2011; 74: 593–602
- 19 Brown SR, Baraza W. Chromoscopy versus conventional endoscopy for the detection of polyps in the colon and rectum. *Cochrane Database Syst Rev* 2010: DOI 10.1002/14651858.CD006439.pub3 CD006439
- 20 Pohl J, Schneider A, Vogell H et al. Pancolonic chromoendoscopy with indigo carmine versus standard colonoscopy for detection of neoplastic lesions: a randomised two-centre trial. *Gut* 2011; 60: 485–490
- 21 Togashi K, Hewett DG, Radford-Smith GL et al. The use of indigocarmine spray increases the colonoscopic detection rate of adenomas. *J Gastroenterol* 2009; 44: 826–833
- 22 Hashimoto K, Higaki S, Nishihira M et al. Does chromoendoscopy improve the colonoscopic adenoma detection rate? *Hepatogastroenterology* 2010; 57: 1399–1404
- 23 Kahi CJ, Anderson JC, Waxman I et al. High-definition chromocolonoscopy vs. high-definition white light colonoscopy for average-risk colorectal cancer screening. *Am J Gastroenterol* 2010; 105: 1301–1307
- 24 Dinesen L, Chua TJ, Kaffes AJ. Meta-analysis of narrow-band imaging versus conventional colonoscopy for adenoma detection. *Gastrointest Endosc* 2012; 75: 604–611
- 25 Pasha SF, Leighton JA, Das A et al. Comparison of the yield and miss rate of narrow band imaging and white light endoscopy in patients undergoing screening or surveillance colonoscopy: a meta-analysis. *Am J Gastroenterol* 2012; 107: 363–370
- 26 Kaltenbach T, Friedland S, Soetikno R. A randomised tandem colonoscopy trial of narrow band imaging versus white light examination to compare neoplasia miss rates. *Gut* 2008; 57: 1406–1412
- 27 Rex DK, Helbig CC. High yields of small and flat adenomas with high-definition colonoscopes using either white light or narrow band imaging. *Gastroenterology* 2007; 133: 42–47
- 28 Inoue T, Murano M, Murano N et al. Comparative study of conventional colonoscopy and pan-colonic narrow-band imaging system in the detection of neoplastic colonic polyps: a randomized, controlled trial. *J Gastroenterol* 2008; 43: 45–50
- 29 Adler A, Aschenbeck J, Yenerim T et al. Narrow-band versus white-light high definition television endoscopic imaging for screening colonoscopy: a prospective randomized trial. *Gastroenterology* 2009; 136: 410–416 e1; quiz 715
- 30 Paggi S, Radaelli F, Amato A et al. The impact of narrow band imaging in screening colonoscopy: a randomized controlled trial. *Clin Gastroenterol Hepatol* 2009; 7: 1049–1054
- 31 East JE, Ignjatovic A, Suzuki N et al. A randomized, controlled trial of narrow-band imaging vs high-definition white light for adenoma detection in patients at high risk of adenomas. *Colorectal Dis* 2012; 14: e771–e778
- 32 Stipho S, Gilani N, Ramirez F. The clinical utility of high-definition magnification endoscopy with and without narrow band imaging for detection of colonic neoplasia. *Gastrointest Endosc* 2008; 67: AB130
- 33 Glenn T, Hoffmann BJ, Romagnuolo J et al. Does narrow band imaging (NBI) enhance colon polyp detection? *Gastrointest Endosc* 2005; 61: AB227
- 34 Inaba Y, Watari J, Okamoto K et al. Usefulness of narrow band imaging as a digital chromoendoscopy in screening colonoscopy: a prospective pilot study. *Gastrointest Endosc* 2005; 61: AB228
- 35 Sabbagh LC, Reveiz L, Aponte D et al. Narrow-band imaging does not improve detection of colorectal polyps when compared to conventional colonoscopy: a randomized controlled trial and meta-analysis of published studies. *BMC Gastroenterol* 2011; 11: 100
- 36 Pohl J, Lotterer E, Balzer C et al. Computed virtual chromoendoscopy versus standard colonoscopy with targeted indigocarmine chromoscopy: a randomised multicentre trial. *Gut* 2009; 58: 73–78
- 37 Chung SJ, Kim D, Song JH et al. Efficacy of computed virtual chromoendoscopy on colorectal cancer screening: a prospective, randomized, back-to-back trial of Fuji Intelligent Color Enhancement versus conventional colonoscopy to compare adenoma miss rates. *Gastrointest Endosc* 2010; 72: 136–142
- 38 Hong SN, Choe WH, Lee JH et al. Prospective, randomized, back-to-back trial evaluating the usefulness of i-SCAN in screening colonoscopy. *Gastrointest Endosc* 2012; 75: 1011–1021.e2
- 39 Kuiper T, van den Broek FJ, Naber AH et al. Endoscopic trimodal imaging detects colonic neoplasia as well as standard video endoscopy. *Gastroenterology* 2011; 140: 1887–1894
- 40 van den Broek FJ, Fockens P, Van Eeden S et al. Clinical evaluation of endoscopic trimodal imaging for the detection and differentiation of colonic polyps. *Clin Gastroenterol Hepatol* 2009; 7: 288–295
- 41 Matsuda T, Saito Y, Fu KI et al. Does autofluorescence imaging videoscopy system improve the colonoscopic polyp detection rate? –a pilot study *Am J Gastroenterol* 2008; 103: 1926–1932
- 42 Takeuchi Y, Inoue T, Hanaoka N et al. Autofluorescence imaging with a transparent hood for detection of colorectal neoplasms: a prospective, randomized trial. *Gastrointest Endosc* 2010; 72: 1006–1013
- 43 Rotondano G, Bianco MA, Sansone S et al. Trimodal endoscopic imaging for the detection and differentiation of colorectal adenomas: a prospective single-centre clinical evaluation. *Int J Colorectal Dis* 2012; 27: 331–336
- 44 He Q, Li JD, An SL et al. Cap-assisted colonoscopy versus conventional colonoscopy: systematic review and meta-analysis. *Int J Colorectal Dis* 2013; 28: 279–281
- 45 Ng SC, Tsoi KKF, Hirai HW et al. The efficacy of cap-assisted colonoscopy in polyp detection and cecal intubation: a meta-analysis of randomized controlled trials. *Am J Gastroenterol* 2012; 107: 1165–1173
- 46 Westwood DA, Alexakis N, Connor SJ. Transparent cap-assisted colonoscopy versus standard adult colonoscopy: a systematic review and meta-analysis. *Dis Colon Rectum* 2012; 55: 218–225
- 47 Morgan J, Thomas K, Lee-Robichaud H et al. Transparent cap colonoscopy versus standard colonoscopy for investigation of gastrointestinal tract conditions. *Cochrane Database Syst Rev* 16. 02 2011; 2: DOI 10.1002/14651858.CD008211.pub2
- 48 Leufkens AM, DeMarco DC, Rastogi A. Effect of a retrograde-viewing device on adenoma detection rate during colonoscopy: the TERRACE study. *Gastrointest Endosc* 2011; 73: 480–489
- 49 Mamula P, Tierney WM, Banerjee S et al. Devices to improve colon polyp detection. *Gastrointest Endosc* 2011; 73: 1092–1097
- 50 Wallace MH, Frayling IM, Clark SK et al. Attenuated adenomatous polyposis coli: the role of ascertainment bias through failure to dye-spray at colonoscopy. *Dis Colon Rectum* 1999; 42: 1078–1080

- 51 East JE, Saunders BP, Jass JR. Sporadic and syndromic hyperplastic polyps and serrated adenomas of the colon: classification, molecular genetics, natural history, and clinical management. *Gastroenterol Clin North Am* 2008; 37: 25–46
- 52 Jarvinen HJ, Aarnio M, Mustonen H et al. Controlled 15-year trial on screening for colorectal cancer in families with hereditary nonpolyposis colorectal cancer. *Gastroenterology* 2000; 118: 829–834
- 53 Cairns SR, Scholefield JH, Steele RJ et al. Guidelines for colorectal cancer screening and surveillance in moderate and high risk groups (update from 2002). *Gut* 2010; 59: 666–689
- 54 Rex DK, Ahnen DJ, Baron JA et al. Serrated lesions of the colorectum: review and recommendations from an expert panel. *Am J Gastroenterol* 2012; 107: 1315–1329; quiz 1314, 1330
- 55 Boparai KS, Mathus-Vliegen EM, Koornstra JJ et al. Increased colorectal cancer risk during follow-up in patients with hyperplastic polyposis syndrome: a multicentre cohort study. *Gut* 2010; 59: 1094–1100
- 56 Vasen HF, Abdurahman M, Brohet R et al. One to 2-year surveillance intervals reduce risk of colorectal cancer in families with Lynch syndrome. *Gastroenterology* 2010; 138: 2300–2306
- 57 Rondagh EJ, Gulikers S, Gomez-Garcia EB et al. Nonpolypoid colorectal neoplasms: a challenge in endoscopic surveillance of patients with Lynch syndrome. *Endoscopy* 2013; 45: 257–264
- 58 Hazewinkel Y, Lopez-Ceron M, East JE et al. Endoscopic features of sessile serrated adenomas: validation by international experts using high-resolution white-light endoscopy and narrow-band imaging. *Gastrointest Endosc* 2013; 77: 916–924
- 59 Hurlstone DP, Karajeh M, Cross SS et al. The role of high-magnification-chromoscopic colonoscopy in hereditary nonpolyposis colorectal cancer screening: a prospective “back-to-back” endoscopic study. *Am J Gastroenterol* 2005; 100: 2167–2173
- 60 Lecomte T, Cellier C, Meatchi T et al. Chromoendoscopic colonoscopy for detecting preneoplastic lesions in hereditary nonpolyposis colorectal cancer syndrome. *Clin Gastroenterol Hepatol* 2005; 3: 897–902
- 61 Huneburg R, Lammert F, Rabe C et al. Chromocolonoscopy detects more adenomas than white light colonoscopy or narrow band imaging colonoscopy in hereditary nonpolyposis colorectal cancer screening. *Endoscopy* 2009; 41: 316–322
- 62 Stoffel EM, Turgeon DK, Stockwell DH et al. Missed adenomas during colonoscopic surveillance in individuals with Lynch syndrome (hereditary nonpolyposis colorectal cancer). *Cancer Prev Res (Phila)* 2008; 1: 470–475
- 63 East JE, Suzuki N, Stavrinidis M et al. Narrow band imaging for colonoscopic surveillance in hereditary non-polyposis colorectal cancer. *Gut* 2008; 57: 65–70
- 64 Bisschops R, Tejpar S, Willekens H et al. I-scan detects more polyps in Lynch Syndrome (HNPPC) patients: a prospective controlled randomized back-to-back study. *Gastrointest Endosc* 2012; 75: AB330
- 65 Ramsoekh D, Haringsma J, Poley JW et al. A back-to-back comparison of white light video endoscopy with autofluorescence endoscopy for adenoma detection in high-risk subjects. *Gut* 2010; 59: 785–793
- 66 Boparai KS, van den Broek FJ, van Eeden S et al. Increased polyp detection using narrow band imaging compared with high resolution endoscopy in patients with hyperplastic polyposis syndrome. *Endoscopy* 2011; 43: 676–682
- 67 Boparai KS, van den Broek FJ, van Eeden S et al. Hyperplastic polyposis syndrome: a pilot study for the differentiation of polyps by using high-resolution endoscopy, autofluorescence imaging, and narrow-band imaging. *Gastrointest Endosc* 2009; 70: 947–955
- 68 Soravia C, Berk T, Madlensky L et al. Genotype-phenotype correlations in attenuated adenomatous polyposis coli. *Am J Hum Genet* 1998; 62: 1290–1301
- 69 Heiskanen I, Luostarinen T, Jarvinen HJ. Impact of screening examinations on survival in familial adenomatous polyposis. *Scand J Gastroenterol* 2000; 35: 1284–1287
- 70 Matsumoto T, Esaki M, Fujisawa R et al. Chromoendoscopy, narrow-band imaging colonoscopy, and autofluorescence colonoscopy for detection of diminutive colorectal neoplasia in familial adenomatous polyposis. *Dis Colon Rectum* 2009; 52: 1160–1165
- 71 Friederich P, de Jong AE, Mathus-Vliegen LM et al. Risk of developing adenomas and carcinomas in the ileal pouch in patients with familial adenomatous polyposis. *Clin Gastroenterol Hepatol* 2008; 6: 1237–1242
- 72 Tajika M, Nakamura T, Nakahara O et al. Prevalence of adenomas and carcinomas in the ileal pouch after proctocolectomy in patients with familial adenomatous polyposis. *J Gastrointest Surg* 2009; 13: 1266–1273
- 73 Van Assche G, Dignass A, Bokemeyer B et al. Second European evidence-based consensus on the diagnosis and management of ulcerative colitis part 3: special situations. *J Crohns Colitis* 2013; 7: 1–33
- 74 Rutter MD, Saunders BP, Wilkinson KH et al. Thirty-year analysis of a colonoscopic surveillance program for neoplasia in ulcerative colitis. *Gastroenterology* 2006; 130: 1030–1038
- 75 Watanabe K, Sogawa M, Yamagami H et al. Endoscopic differential diagnosis between ulcerative colitis-associated neoplasia and sporadic neoplasia in surveillance colonoscopy using narrow band imaging. *Dig Endosc* 2011; 23: 01143–149
- 76 Hurlstone DP, Sanders DS, Atkinson R et al. Endoscopic mucosal resection for flat neoplasia in chronic ulcerative colitis: can we change the endoscopic management paradigm? *Gut* 2007; 56: 838–846
- 77 Kiesslich R, Fritsch J, Holtmann M et al. Methylene blue-aided chromoendoscopy for the detection of intraepithelial neoplasia and colon cancer in ulcerative colitis. *Gastroenterology* 2003; 124: 880–888
- 78 Kiesslich R, Goetz M, Lammersdorf K et al. Chromoscopy-guided endomicroscopy increases the diagnostic yield of intraepithelial neoplasia in ulcerative colitis. *Gastroenterology* 2007; 132: 874–882
- 79 Subramanian V, Mannath J, Ragunath K et al. Meta-analysis: the diagnostic yield of chromoendoscopy for detecting dysplasia in patients with colonic inflammatory bowel disease. *Aliment Pharmacol Ther* 2011; 33: 304–312
- 80 Hlavaty T, Huorka M, Koller T et al. Colorectal cancer screening in patients with ulcerative and Crohn's colitis with use of colonoscopy, chromoendoscopy and confocal endomicroscopy. *Eur J Gastroenterol Hepatol* 2011; 23: 680–689
- 81 Gunther U, Kusch D, Heller F et al. Surveillance colonoscopy in patients with inflammatory bowel disease: comparison of random biopsy vs. targeted biopsy protocols. *Int J Colorectal Dis* 2011; 26: 667–672
- 82 Hurlstone DP, Sanders DS, Lobo AJ et al. Indigo carmine-assisted high-magnification chromoscopic colonoscopy for the detection and characterisation of intraepithelial neoplasia in ulcerative colitis: a prospective evaluation. *Endoscopy* 2005; 37: 1186–1192
- 83 Matsumoto T, Nakamura S, Jo Y et al. Chromoscopy might improve diagnostic accuracy in cancer surveillance for ulcerative colitis. *Am J Gastroenterol* 2003; 98: 1827–1833
- 84 Rutter MD, Saunders BP, Schofield G et al. Pancolonic indigo carmine dye spraying for the detection of dysplasia in ulcerative colitis. *Gut* 2004; 53: 256–260
- 85 Marion JF, Waye JD, Present DH et al. Chromoendoscopy-targeted biopsies are superior to standard colonoscopic surveillance for detecting dysplasia in inflammatory bowel disease patients: a prospective endoscopic trial. *Am J Gastroenterol* 2008; 103: 2342–2349
- 86 Eaden JA, Ward BA, Mayberry JF. How gastroenterologists screen for colonic cancer in ulcerative colitis: an analysis of performance. *Gastrointest Endosc* 2000; 51: 123–128
- 87 Olliver JR, Wild CP, Sahay P et al. Chromoendoscopy with methylene blue and associated DNA damage in Barrett's oesophagus. *Lancet* 2003; 362: 373–374
- 88 Elsadani NN, East JE, Walters JR. New 2010 British Society of Gastroenterology colitis surveillance guidelines: costs and surveillance intervals. *Gut* 2011; 60: 282–283
- 89 Kiesslich R, Neurath MF. Surveillance colonoscopy in ulcerative colitis: magnifying chromoendoscopy in the spotlight. *Gut* 2004; 53: 165–167
- 90 Cairns SR, Scholefield JH, Steele RJ et al. Guidelines for colorectal cancer screening and surveillance in moderate and high risk groups (update from 2002). *Gut* 2010; 59: 666–689
- 91 Annese V, Daperno M, Rutter MD et al. European evidence based consensus for endoscopy in inflammatory bowel disease. *J Crohns Colitis* 2013; 7: 982–1018
- 92 Ignjatovic A, East JE, Subramanian V et al. Narrow band imaging for detection of dysplasia in colitis: a randomized controlled trial. *Am J Gastroenterol* 2012; 107: 885–890

- 93 Dekker E, van den Broek FJ, Reitsma JB et al. Narrow-band imaging compared with conventional colonoscopy for the detection of dysplasia in patients with longstanding ulcerative colitis. *Endoscopy* 2007; 39: 216–221
- 94 van den Broek FJ, Fockens P, van Eeden S et al. Endoscopic tri-modal imaging for surveillance in ulcerative colitis: randomised comparison of high-resolution endoscopy and autofluorescence imaging for neoplasia detection; and evaluation of narrow-band imaging for classification of lesions. *Gut* 2008; 57: 1083–1089
- 95 Pellise M, Lopez-Ceron M, Rodriguez de Miguel C et al. Narrow-band imaging as an alternative to chromoendoscopy for the detection of dysplasia in long-standing inflammatory bowel disease: a prospective, randomized, crossover study. *Gastrointest Endosc* 2011; 74: 840–848
- 96 Bisschops R, Bessissow T, Baert FJ et al. Chromoendoscopy versus narrow band imaging in ulcerative colitis: a prospective randomized controlled trial. *Gastrointest Endosc* 2012; 75: AB148
- 97 Matsumoto T, Nakamura S, Moriyama T et al. Autofluorescence imaging colonoscopy for the detection of dysplastic lesions in ulcerative colitis: a pilot study. *Colorectal Dis* 2010; 12: e291–e297
- 98 van den Broek FJ, Fockens P, van Eeden S et al. Narrow-band imaging versus high-definition endoscopy for the diagnosis of neoplasia in ulcerative colitis. *Endoscopy* 2011; 43: 108–115
- 99 Matsumoto T, Kudo T, Jo Y et al. Magnifying colonoscopy with narrow band imaging system for the diagnosis of dysplasia in ulcerative colitis: a pilot study. *Gastrointest Endosc* 2007; 66: 957–965
- 100 East JE, Suzuki N, von Herbay A et al. Narrow band imaging with magnification for dysplasia detection and pit pattern assessment in ulcerative colitis surveillance: a case with multiple dysplasia associated lesions or masses. *Gut* 2006; 55: 1432–1435
- 101 Regula J, Rupinski M, Kraszewska E et al. Colonoscopy in colorectal-cancer screening for detection of advanced neoplasia. *N Engl J Med* 2006; 355: 1863–1872
- 102 Gschwantler M, Kriwanek S, Langner E et al. High-grade dysplasia and invasive carcinoma in colorectal adenomas: a multivariate analysis of the impact of adenoma and patient characteristics. *Eur J Gastroenterol Hepatol* 2002; 14: 183–188
- 103 Ignjatovic A, East JE, Suzuki N et al. Optical diagnosis of small colorectal polyps at routine colonoscopy (Detect InSpect ChARacterise Resect and Discard; DISCARD trial): a prospective cohort study. *Lancet Oncol* 2009; 10: 1171–1178
- 104 Kiesslich R, von Bergh M, Hahn M et al. Chromoendoscopy with indigocarmine improves the detection of adenomatous and nonadenomatous lesions in the colon. *Endoscopy* 2001; 33: 1001–1006
- 105 Ignjatovic A, East JE, Guenther T et al. What is the most reliable imaging modality for small colonic polyp characterization? Study of white-light, autofluorescence, and narrow-band imaging *Endoscopy* 2011; 43: 94–99
- 106 Rex DK, Kahi C, O'Brien M et al. The American Society for Gastrointestinal Endoscopy PIVI (Preservation and Incorporation of Valuable Endoscopic Innovations) on real-time endoscopic assessment of the histology of diminutive colorectal polyps. *Gastrointest Endosc* 2011; 73: 419–422
- 107 Granqvist S, Gabrielsson N, Sundelin P. Diminutive colonic polyps – clinical significance and management. *Endoscopy* 1979; 11: 36–42
- 108 Church JM, Fazio VW, Jones IT. Small colorectal polyps. Are they worth treating? *Dis Colon Rectum* 1988; 31: 50–53
- 109 O'Brien MJ, Winawer SJ, Zauber AG et al. The National Polyp Study. Patient and polyp characteristics associated with high-grade dysplasia in colorectal adenomas. *Gastroenterology* 1990; 98: 371–379
- 110 Weston AP, Campbell DR. Diminutive colonic polyps: histopathology, spatial distribution, concomitant significant lesions, and treatment complications. *Am J Gastroenterol* 1995; 90: 24–28
- 111 Read TE, Read JD, Butterly LF. Importance of adenomas 5 mm or less in diameter that are detected by sigmoidoscopy. *NEJM* 1997; 336: 8–12
- 112 Nusko G, Mansmann U, Altendorf-Hofmann A et al. Risk of invasive carcinoma in colorectal adenomas assessed by size and site. *Int J Colorectal Dis* 1997; 12: 267–271
- 113 Aldridge AJ, Simson JN. Histological assessment of colorectal adenomas by size. Are polyps less than 10 mm in size clinically important? *Eur J Surg* 2001; 167: 777–781
- 114 Pickhardt PJ, Choi JR, Hwang I et al. Computed tomographic virtual colonoscopy to screen for colorectal neoplasia in asymptomatic adults. *NEJM* 2003; 349: 2191–2200
- 115 Church JM. Clinical significance of small colorectal polyps. *Dis Colon Rectum* 2004; 47: 481–485
- 116 O'Brien MJ, Winawer SJ, Zauber AG et al. Flat adenomas in the National Polyp Study: is there increased risk for high-grade dysplasia initially or during surveillance? *Clin Gastroenterol Hepatol* 2004; 2: 905–911
- 117 Souques M, Lassalle M, Guldner L et al. Colorectal polyps and cancers diagnosed by pathologists in Ile de France region. Crisapif-Petri Study. *Gastroenterol Clin Biol* 2006; 30: 587–593
- 118 Chen SC, Mouchli A, Chadalawada V et al. Histopathology of small polyps removed in the videoendoscopic era. *Gastrointest Endosc* 2006; 63: AB199
- 119 Butterly LF, Chase MP, Pohl H et al. Prevalence of clinically important histology in small adenomas. *Clin Gastroenterol Hepatol* 2006; 4: 343–348
- 120 Kim DH, Pickhardt PJ, Taylor AJ et al. CT colonography versus colonoscopy for the detection of advanced neoplasia. *NEJM* 2007; 357: 1403–1412
- 121 Yoo TW, Park DJ, Kim YH et al. Clinical significance of small colorectal adenoma less than 10 mm: the KASID study. *Hepatogastroenterology* 2007; 54: 418–421
- 122 Lieberman D, Moravec M, Holub J et al. Polyp size and advanced histology in patients undergoing colonoscopy screening: implications for CT colonography. *Gastroenterology* 2008; 135: 1100–1105
- 123 Rex DK, Overhiser AJ, Chen SC et al. Estimation of impact of American College of Radiology recommendations on CT colonography reporting for resection of high-risk adenoma findings. *American J Gastroenterol* 2009; 104: 149–153
- 124 Graser A, Stieber P, Nagel D et al. Comparison of CT colonography, colonoscopy, sigmoidoscopy and faecal occult blood tests for the detection of advanced adenoma in an average risk population. *Gut* 2009; 58: 241–248
- 125 Bretagne JF, Manfredi S, Piette C et al. Yield of high-grade dysplasia based on polyp size detected at colonoscopy: a series of 2295 examinations following a positive fecal occult blood test in a population-based study. *Dis Colon Rectum* 2010; 53: 339–345
- 126 Denis B, Bottlaender J, Weiss AM et al. Some diminutive colorectal polyps can be removed and discarded without pathological examination. *Endoscopy* 2011; 43: 81–86
- 127 Chaput U, Alberto SF, Terris B et al. Risk factors for advanced adenomas amongst small and diminutive colorectal polyps: a prospective monocenter study. *Dig Liver Dis* 2011; 43: 609–612
- 128 Repici A, Hassan C, Vitetta E et al. Safety of cold polypectomy for <10mm polyps at colonoscopy: a prospective multicenter study. *Endoscopy* 2012; 44: 27–31
- 129 Tsai FC, Strum WB. Prevalence of advanced adenomas in small and diminutive colon polyps using direct measurement of size. *Dig Dis Sci* 2011; 56: 2384–2388
- 130 Shapiro R, Ben-Horin S, Bar-Meir S et al. The risk of advanced histology in small-sized colonic polyps: are non-invasive colonic imaging modalities good enough? *Int J Colorectal Dis* 2012; 27: 1071–1075
- 131 Kolligs FT, Crispin A, Graser A et al. Risk factors for advanced neoplasia within subcentimetric polyps: implications for diagnostic imaging. *Gut* 2012; 62: 863–870 doi: DOI 10.1136/gutjnl-2011-300111 Epub 2012 Apr 23
- 132 Gupta N, Bansal A, Rao D et al. Prevalence of advanced histological features in diminutive and small colon polyps. *Gastrointest Endosc* 2012; 75: 1022–1030
- 133 Terry MB, Neugut AI, Bostick RM et al. Reliability in the classification of advanced colorectal adenomas. *Cancer Epidemiol Biomarkers Prev* 2002; 11: 660–663
- 134 Costantini M, Sciallero S, Giannini A et al. Interobserver agreement in the histologic diagnosis of colorectal polyps. the experience of the multicenter adenoma colorectal study (SMAC). *J Clin Epidemiol* 2003; 56: 209–214
- 135 Lasisi F, Mouchli A, Riddell R et al. Agreement in interpreting villous elements and dysplasia in adenomas less than one centimetre in size. *Dig Liver Dis* 2013; 45: 1049–1055
- 136 Atkin WS, Valori R, Kuipers EJ et al. European guidelines for quality assurance in colorectal cancer screening and diagnosis. First Edition–Colonoscopic surveillance following adenoma removal. *Endoscopy* 2012; 44: E151–163
- 137 Lieberman DA, Rex DK, Winawer SJ et al. Guidelines for colonoscopy surveillance after screening and polypectomy: a consensus update by the US Multi-Society Task Force on Colorectal Cancer. *Gastroenterology* 2012; 143: 844–857

- 138 Hassan C, Quintero E, Dumonceau JM et al. Post-polypectomy colonoscopy surveillance: European Society of Gastrointestinal Endoscopy (ESGE) Guideline. *Endoscopy* 2013; 45: 842–864
- 139 Endoscopic Classification Review Group. Update on the Paris classification of superficial neoplastic lesions in the digestive tract. *Endoscopy* 2005; 37: 570–578
- 140 Longcroft-Wheaton G, Brown J, Cowlshaw D et al. High-definition vs. standard-definition colonoscopy in the characterization of small colonic polyps: results from a randomized trial. *Endoscopy* 2012; 44: 905–910
- 141 McGill SK, Evangelou E, Ioannidis JP et al. Narrow band imaging to differentiate neoplastic and non-neoplastic colorectal polyps in real time: a meta-analysis of diagnostic operating characteristics. *Gut* 2013; 62: 1704–1713 DOI 10.1136/gutjnl-2012-303965
- 142 Togashi K, Osawa H, Koinuma K et al. A comparison of conventional endoscopy, chromoendoscopy, and the optimal-band imaging system for the differentiation of neoplastic and non-neoplastic colonic polyps. *Gastrointest Endosc* 2009; 69: 734–741
- 143 Ladabaum U, Fioritto A, Mitani A et al. Real-time optical biopsy of colon polyps with narrow band imaging in community practice does not yet meet key thresholds for clinical decisions. *Gastroenterology* 2013; 144: 81–91
- 144 Paggi S, Rondonotti E, Amato A et al. Resect and discard strategy in clinical practice: a prospective cohort study. *Endoscopy* 2012; 44: 899–904
- 145 Schachschal G, Mayr M, Treszl A et al. Endoscopic versus histological characterisation of polyps during screening colonoscopy. *Gut* 2013; DOI 10.1136/gutjnl-2013-304562
- 146 Masci E, Mangiavillano B, Crosta C et al. Interobserver agreement among endoscopists on evaluation of polypoid colorectal lesions visualized with the Pentax i-Scan technique. *Dig Liver Dis* 2013; 45: 207–210
- 147 Pigo F, Bertani H, Manno M et al. i-Scan high-definition white light endoscopy and colorectal polyps: prediction of histology, interobserver and intraobserver agreement. *Int J Colorectal Dis* 2013; 28: 399–406
- 148 van den Broek FJ, van Soest EJ, Naber AH et al. Combining autofluorescence imaging and narrow-band imaging for the differentiation of adenomas from non-neoplastic colonic polyps among experienced and non-experienced endoscopists. *Am J Gastroenterol* 2009; 104: 1498–1507
- 149 Rastogi A, Pondugula K, Bansal A et al. Recognition of surface mucosal and vascular patterns of colon polyps by using narrow-band imaging: interobserver and intraobserver agreement and prediction of polyp histology. *Gastrointest Endosc* 2009; 69: 716–22
- 150 Huang Q, Fukami N, Kashida H et al. Interobserver and intra-observer consistency in the endoscopic assessment of colonic pit patterns. *Gastrointest Endosc* 2004; 60: 520–526
- 151 East JE, Suzuki N, Saunders BP. Comparison of magnified pit pattern interpretation with narrow band imaging versus chromoendoscopy for diminutive colonic polyps: a pilot study. *Gastrointest Endosc* 2007; 66: 310–316
- 152 Sato R, Fujiya M, Watari J et al. The diagnostic accuracy of high-resolution endoscopy, autofluorescence imaging and narrow-band imaging for differentially diagnosing colon adenoma. *Endoscopy* 2011; 43: 862–868
- 153 Rogart JN, Jain D, Siddiqui UD et al. Narrow-band imaging without high magnification to differentiate polyps during real-time colonoscopy: improvement with experience. *Gastrointest Endosc* 2008; 68: 1136–1145
- 154 East JE, Suzuki N, Bassett P et al. Narrow band imaging with magnification for the characterization of small and diminutive colonic polyps: pit pattern and vascular pattern intensity. *Endoscopy* 2008; 40: 811–817
- 155 Ignjatovic A, Thomas-Gibson S, East JE et al. Development and validation of a training module on the use of narrow-band imaging in differentiation of small adenomas from hyperplastic colorectal polyps. *Gastrointest Endosc* 2011; 73: 128–133
- 156 Raghavendra M, Hewett DG, Rex DK. Differentiating adenomas from hyperplastic colorectal polyps: narrow-band imaging can be learned in 20 minutes. *Gastrointest Endosc* 2010; 72: 572–576
- 157 Rastogi A, Rao DS, Gupta N et al. Impact of a computer-based teaching module on characterization of diminutive colon polyps by using narrow-band imaging by non-experts in academic and community practice: a video-based study. *Gastrointest Endosc* 2013; DOI 10.1016/j.gie.2013.07.032 [Epub ahead of print]
- 158 Higashi R, Uraoka T, Kato J et al. Diagnostic accuracy of narrow-band imaging and pit pattern analysis significantly improved for less-experienced endoscopists after an expanded training program. *Gastrointest Endosc* 2010; 72: 127–135
- 159 Hewett DG, Kaltenbach T, Sano Y et al. Validation of a simple classification system for endoscopic diagnosis of small colorectal polyps using narrow-band imaging. *Gastroenterology* 2012; 143: 599–607.e1
- 160 Kumar S, Fioritto A, Mitani A et al. Optical biopsy of sessile serrated adenomas: do these lesions resemble hyperplastic polyps under narrow-band imaging? *Gastrointest Endosc* 2013; 78: 902–909 DOI 10.1016/j.gie.2013.06.004
- 161 Varnavas A, Ignjatovic A, Bharath A et al. Classification of colon images using the magnitude of orientation dominance. *Proceedings of the 5th UKRI PG Conference in Biomedical Engineering and Medical Physics* 2009; 1: 13–14
- 162 Tischendorf JJ, Gross S, Winograd R et al. Computer-aided classification of colorectal polyps based on vascular patterns: a pilot study. *Endoscopy* 2010; 42: 203–207
- 163 Takemura Y, Yoshida S, Tanaka S et al. Computer-aided system for predicting the histology of colorectal tumors by using narrow-band imaging magnifying colonoscopy (with video). *Gastrointest Endosc* 2012; 75: 179–185
- 164 Gross S, Trautwein C, Behrens A et al. Computer-based classification of small colorectal polyps by using narrow-band imaging with optical magnification. *Gastrointest Endosc* 2011; 74: 1354–1359
- 165 Gupta N, Bansal A, Rao D et al. Accuracy of in vivo optical diagnosis of colon polyp histology by narrow-band imaging in predicting colonoscopy surveillance intervals. *Gastrointest Endosc* 2012; 75: 494–502
- 166 Longcroft-Wheaton GR, Higgins B, Bhandari P. Flexible spectral imaging color enhancement and indigo carmine in neoplasia diagnosis during colonoscopy: a large prospective UK series. *Eur J Gastroenterol Hepatol* 2011; 23: 903–911
- 167 Hassan C, Pickhardt PJ, Rex DK. A resect and discard strategy would improve cost-effectiveness of colorectal cancer screening. *Clin Gastroenterol Hepatol* 2010; 8: 865–869, 869e1–e3
- 168 Valori R, Rey JF, Atkin WS et al. European guidelines for quality assurance in colorectal cancer screening and diagnosis. First edition—Quality assurance in endoscopy in colorectal cancer screening and diagnosis. *Endoscopy* 2012; 44: E88–105
- 169 Steele RJ, Pox C, Kuipers EJ et al. European guidelines for quality assurance in colorectal cancer screening and diagnosis. First edition—Management of lesions detected in colorectal cancer screening. *Endoscopy* 2012; 44: E140–50
- 170 Watanabe T, Itabashi M, Shimada Y et al. Japanese Society for Cancer of the Colon and Rectum (JSCCR) guidelines 2010 for the treatment of colorectal cancer. *Int J Clin Oncol* 2012; 17: 1–29
- 171 Nakadoi K, Tanaka S, Kanao H et al. Management of T1 colorectal carcinoma with special reference to criteria for curative endoscopic resection. *J Gastroenterol Hepatol* 2012; 27: 1057–1062
- 172 Kudo S, Rubio CA, Teixeira CR et al. Pit pattern in colorectal neoplasia: endoscopic magnifying view. *Endoscopy* 2001; 33: 367–373
- 173 Hirata M, Tanaka S, Oka S et al. Evaluation of microvessels in colorectal tumors by narrow band imaging magnification. *Gastrointest Endosc* 2007; 66: 945–952
- 174 Fujii T, Hasegawa RT, Saitoh Y et al. Chromoscopy during colonoscopy. *Endoscopy* 2001; 33: 1036–1041
- 175 Nagata S, Tanaka S, Haruma K et al. Pit pattern diagnosis of early colorectal carcinoma by magnifying colonoscopy: clinical and histological implications. *Int J Oncol* 2000; 16: 927–934
- 176 Kudo S, Lambert R, Allen JJ et al. Nonpolypoid neoplastic lesions of the colorectal mucosa. *Gastrointest Endosc* 2008; 68: 3–S47
- 177 Bianco MA, Rotondano G, Marmo R et al. Predictive value of magnification chromoendoscopy for diagnosing invasive neoplasia in nonpolypoid colorectal lesions and stratifying patients for endoscopic resection or surgery. *Endoscopy* 2006; 38: 470–476
- 178 Kanao H, Tanaka S, Oka S et al. Narrow-band imaging magnification predicts the histology and invasion depth of colorectal tumors. *Gastrointest Endosc* 2009; 69: 631–636
- 179 Wada Y, Kudo SE, Kashida H et al. Diagnosis of colorectal lesions with the magnifying narrow-band imaging system. *Gastrointest Endosc* 2009; 70: 522–531

- 180 *Matsumoto K, Nagahara A, Terai T* et al. Evaluation of new subclassification of type V(I) pit pattern for determining the depth and type of invasion of colorectal neoplasm. *J Gastroenterol* 2011; 46: 31–38
- 181 *Kanao H, Tanaka S, Oka S* et al. Clinical significance of type V(I) pit pattern subclassification in determining the depth of invasion of colorectal neoplasms. *World J Gastroenterol* 2008; 14: 211–217
- 182 *Kobayashi N, Saito Y, Sano Y* et al. Determining the treatment strategy for colorectal neoplastic lesions: endoscopic assessment or the non-lifting sign for diagnosing invasion depth? *Endoscopy* 2007; 39: 701–705
- 183 *Saitoh Y, Obara T, Watari J* et al. Invasion depth diagnosis of depressed type early colorectal cancers by combined use of videoendoscopy and chromoendoscopy. *Gastrointest Endosc* 1998; 48: 362–370
- 184 *Matsuda T, Fujii T, Saito Y* et al. Efficacy of the invasive/non-invasive pattern by magnifying chromoendoscopy to estimate the depth of invasion of early colorectal neoplasms. *Am J Gastroenterol* 2008; 103: 2700–2706
- 185 *Hayashi N, Tanaka S, Hewett DG* et al. Endoscopic prediction of deep submucosal invasive carcinoma: validation of the narrow-band imaging international colorectal endoscopic (NICE) classification. *Gastrointest Endosc* 2013; 78: 625–632 doi: DOI 10.1016/j.gie.2013.04.185
- 186 *Tsuda S, Veress B, Toth E* et al. Flat and depressed colorectal tumours in a southern Swedish population: a prospective chromoendoscopic and histopathological study. *Gut* 2002; 51: 550–555
- 187 *Rembacken BJ, Fujii T, Cairns A* et al. Flat and depressed colonic neoplasms: a prospective study of 1000 colonoscopies in the UK. *Lancet* 2000; 355: 1211–1214
- 188 *Hurlstone DP, Cross SS, Adam I* et al. A prospective clinicopathological and endoscopic evaluation of flat and depressed colorectal lesions in the United Kingdom. *Am J Gastroenterol* 2003; 98: 2543–2549
- 189 *Soetikno RM, Kaltenbach T, Rouse RV* et al. Prevalence of nonpolypoid (flat and depressed) colorectal neoplasms in asymptomatic and symptomatic adults. *JAMA* 2008; 299: 1027–1035
- 190 *Diebold MD, Samalin E, Merle C* et al. Colonic flat neoplasia: frequency and concordance between endoscopic appearance and histological diagnosis in a French prospective series. *Am J Gastroenterol* 2004; 99: 1795–1800
- 191 *Rotondano G, Bianco MA, Buffoli F* et al. The Cooperative Italian FLIN Study Group: prevalence and clinico-pathological features of colorectal laterally spreading tumors. *Endoscopy* 2011; 43: 856–861
- 192 *Bianco MA, Cipolletta L, Rotondano G* et al. Prevalence of nonpolypoid colorectal neoplasia: an Italian multicenter observational study. *Endoscopy* 2010; 42: 279–285
- 193 *Robertson DJ, Greenberg ER, Beach M* et al. Colorectal cancer in patients under close colonoscopic surveillance. *Gastroenterology* 2005; 129: 34–41
- 194 *Pabby A, Schoen RE, Weissfeld JL* et al. Analysis of colorectal cancer occurrence during surveillance colonoscopy in the dietary Polyp Prevention Trial. *Gastrointest Endosc* 2005; 61: 385–391
- 195 *Pohl H, Srivastava A, Bensen SP* et al. Incomplete polyp resection during colonoscopy – results of the complete adenoma resection (CARE) study. *Gastroenterology* 2013; 144: 74–80 e1
- 196 *Hurlstone DP, Cross SS, Brown S* et al. A prospective evaluation of high-magnification chromoscopic colonoscopy in predicting completeness of EMR. *Gastrointest Endosc* 2004; 59: 642–650
- 197 *Hurlstone DP, Cross SS, Drew K*. An evaluation of colorectal endoscopic mucosal resection using high-magnification chromoscopic colonoscopy: a prospective study of 1000 colonoscopies. *Endoscopy* 2004; 36: 491–498
- 198 *Moss A, Bourke MJ, Williams SJ* et al. Endoscopic mucosal resection outcomes and prediction of submucosal cancer from advanced colonic mucosal neoplasia. *Gastroenterology* 2011; 140: 1909–1918
- 199 *Buchner AM, Guarner-Argente C, Ginsberg GG*. Outcomes of EMR of defiant colorectal lesions directed to an endoscopy referral center. *Gastrointest Endosc* 2012; 76: 255–263
- 200 *Cipolletta L, Bianco MA, Garofano ML* et al. Can magnification endoscopy detect residual adenoma after piecemeal resection of large sessile colorectal lesions to guide subsequent treatment? A prospective single-center study *Dis Colon Rectum* 2009; 52: 1774–1779
- 201 *Munakata A, Uno Y*. Colonoscopic polypectomy with local injection of methylene blue. *Tohoku J Exp Med* 1994; 173: 377–382
- 202 *Khashab M, Eid E, Rusche M* et al. Incidence and predictors of “late” recurrences after endoscopic piecemeal resection of large sessile adenomas. *Gastrointest Endosc* 2009; 70: 344–349
- 203 *Shahid MW, Buchner AM, Coron E* et al. Diagnostic accuracy of probe-based confocal laser endomicroscopy in detecting residual colorectal neoplasia after EMR: a prospective study. *Gastrointest Endosc* 2012; 75: 525–533
- 204 *Rogart JN, Aslanian HR, Siddiqui UD*. Narrow band imaging to detect residual or recurrent neoplastic tissue during surveillance endoscopy. *Dig Dis Sci* 2011; 56: 472–478
- 205 *Higaki S, Hashimoto S, Harada K* et al. Long-term follow-up of large flat colorectal tumors resected endoscopically. *Endoscopy* 2003; 35: 845–849
- 206 *Hurlstone DP, Sanders DS, Cross SS* et al. Colonoscopic resection of lateral spreading tumours: a prospective analysis of endoscopic mucosal resection. *Gut* 2004; 53: 1334–1339

Appendix e1 – e8

online content viewable at: www.thieme-connect.de